

Case Report

DOI: <http://dx.doi.org/10.22192/ijamr.2018.05.10.002>

## Non-Hodgkin's Large B-cell Non-Hodgkin Lymphoma with skin infiltration in a nursing patient. Case Report and Literature Review

J.A. Román Franco<sup>1</sup>, P. González Galván<sup>2</sup>, R.E. Salgado Sangri<sup>3</sup>

G. Esquivel Martínez<sup>4</sup>, M.A. Murillo<sup>5</sup> D.Piedras González<sup>6</sup>

<sup>1,2</sup> Medical Pediatrics Resident, Escuela de Posgrados en Sanidad Naval. Universidad Naval.

Hospital General Naval de Alta Especialidad. Secretaria de Marina Armada de Mexico (SEMAR),

<sup>3</sup> Pediatric Surgeon Jefe del Departamento de Pediatría Del Hospital General Naval de Alta Especialidad y Profesor de la Especialidad de Pediatría Médica,

<sup>4</sup> Medical Oncologist Pediatrician. Jefe de Especialidades y Subespecialidades Médicas de la Escuela de Posgrados en Sanidad Naval.,

<sup>5</sup> Pediatric Oncologist Physician Médico adscrito al Hospital General Naval de Alta Especialidad

<sup>6</sup> Hematopathology Médico adscrito al Hospital General Naval de Alta Especialidad

### Abstract

**Introduction:** Non-Hodgkin Lymphoma (NHL) represents approximately 7% of those of cancers in children under 20 years of age. Lymphomas are rare in babies ( 1 percent), being characterized by a poor prognosis for that age. **Clinical case:** We report the case of an 8-month-old female infant referred from a Regional Naval Hospital to the Pediatric Oncology Service of the Naval General Hospital of High Specialty with a diagnosis of granuloma in the left iliac fossa probable. Small cell lymphoma in a report lesion biopsy. Complete surgical resection of the lesion was performed with definitive histopathological report Non-Hodgkin's diffuse Large B-cell lymphoma of the marginal zone (CD20 +, MUM1 +, BCL2 +, CD43 +, CD130 + FOCAL, LAMBDA + FOCAL, KI67 in stage IV by infiltration to medulla This is treated with LMB 96 scheme, currently under surveillance. **Discussion:** NHL is rare in pediatric patients under 1 year of age with an incidence of less than 1%. In a retrospective review, the outcome for infants was more precarious compared to older patients with NHL The treatment is aimed at staging with either BFM or FAB / LMB system. **Conclusion:** Diffuse Large B Cell LNH is within the neoplasms with a good prognosis in patients of the second decade of life. life, being the opposite for those below it and even worse for those under the age of 1. It is of vital importance to establish an adequate classification to establish a treatment. timely with the use of new therapies as well as immunohistochemical markers that lead us to guarantee a greater survival without complications for pediatric patients with this disease.

### Keywords

Large Cell Diffuse ,  
Non-Hodgkin  
Lymphoma B /  
Cutaneous  
Lymphomas

## Introduction

Non-Hodgkin Lymphomas (NHL) are malignant diseases which originate from cells belonging to the immune system, specifically lymphoid cells.

## Epidemiology

Lymphoma (Hodgkin's lymphoma and NHL) is the third most common malignant childhood malignancy and, in high-income countries, NHL accounts for approximately 7% of cancers in children under 20 years of age.<sup>1,2</sup>

Diffuse large B-cell lymphoma is a mature B-cell neoplasm representing 10 to 20% of childhood NHL. It is very rare in infants (1% in BFM trials from 1986 to 2002) 3 and accounts for approximately 4% of neoplasms in children aged 1 to 4 years, there is a male predominance, and whites are more commonly affected than African-Americans.<sup>4</sup>

## Classification

Staging of St. Jude Children's Research Hospital (Murphy)<sup>5</sup>

### Stage I childhood non-Hodgkin lymphoma

There is a single tumor or a single committed lymphnode area, with the exception of the abdomen and mediastinum.

### Stage II childhood non-Hodgkin lymphoma

The disease is circumscribed to a single tumor with regional lymphnode involvement, two or more tumors or nodal areas are affected on one side of the diaphragm or there is a primary tumor in the

gastrointestinal tract (totally excised) with regional lymphnode involvement, or without this.

### Childhood Stage III Non-Hodgkin Lymphoma

There are tumors or areas of involved lymphnodes on both sides of the diaphragm. It also includes any primary intrathoracic disease (mediastinal, pleural or thymic), extensive primary intraabdominal disease or any paraspinal or epidural tumor.

### Stage IV childhood non-Hodgkin lymphoma

There are tumors that affect the bone marrow or the CNS, independently of the commitment in other sites. Bone marrow involvement was defined as 5% of malignant cells in a bone marrow without other abnormalities, with normal peripheral blood count and smears. In general, patients with lymphoblastic lymphoma who have more than 25% malignant cells in the bone marrow are considered to have leukemia and can receive adequate treatment in clinical trials of leukemia

### Clinical Case:

Female breastfeeding patient who has a maternal grandmother with lymphoma under surveillance; they live in the countryside, they cook with firewood; He began his illness 6 weeks before admission to this hospital, with the appearance of a nodule in the left inguinal region of a reddish color of approximately 2 x 1 cm. He was treated as an infectious process first because he had a difficult control fever, but he did not respond to antimicrobial treatment, increasing in size, reason for which ultrasound is performed, which reports "granuloma" and a biopsy is decided which reports probable small cell lymphoma; being referred to this hospital.

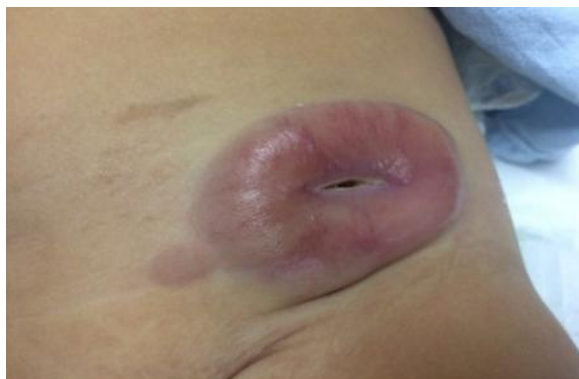
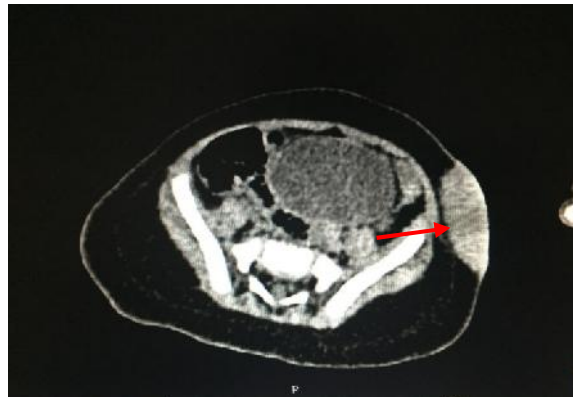
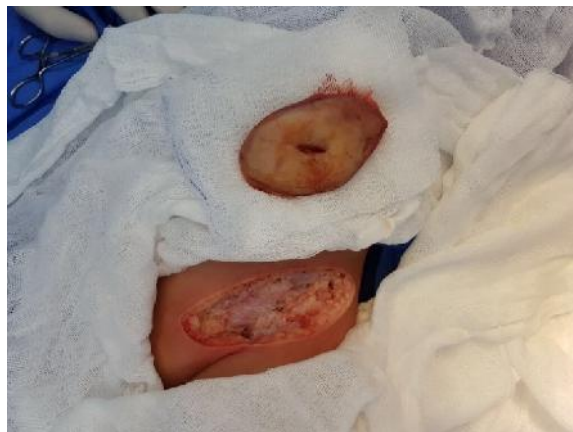Fig.1 Image at the abdominal level showing the lesion with edges defined umbilicated violaceous appearance by taking a biopsy of approximately 5 x 3 x 2 cm.

Physical examination revealed active and reactive female, adequate tegumentary coloration, cylindrical neck without the presence of palpable adenopathies, thorax with symmetrical ventilatory movements without aggregates, heart sounds of adequate intensity and frequency of soft abdomen with no evidence of peritoneal irritation at pit level left iliac presents nodular dermatosis with violaceous surface not fixed to deep planes, indurated consistency well-defined edges (Fig. 1) , limbs without alterations; has laboratory studies with LDH 293 IU / L USG of the lesion is performed, which report anovoid image of partially defined, irregular edges in skin and subcutaneous cellular tissue without exceeding muscular fascia with minimal vascularity; Skin-dependent tumor TAC of 4.8 x 3 x 1.6 cm (Fig.2) that infiltrates subcutaneous cellular tissue without infiltrating muscle fascia 10x3mm satellite lesion with 3

lymphnodes suspected of infiltration; Complete surgical resection is performed (Figure 3) as well as a biopsy which reports a lymphoid neoplastic lesion involving the superficial and deep dermis as well as subcutaneous cellular tissue composed of small and medium lymphocytes, with scarce cytoplasm and oval nucleus with lumpychromatin, atypical mitosis and necrotic center., the report of immunohistochemistry (CD20 +, MUM1 +, BCL2+, CD43+, CD130+FOCAL, LAMBDA + FOCAL, KI67 +,Diffuse Non-Hodgkin Lymphoma of Large Cells B withdefinitivereportisperformedbonemarrowaspiratew hichisreportedwith B-cell NHL infiltration (Figures 4 and 5); it was decided to start treatment with chemotherapy LMB 96 protocol after completing treatment, AMO and PL control were carried out, which are reported without infiltration data initiating their surveillance.



*Fig.2 Tomography image in axial section in simple phase where an ovoid image of 4.8 x 3 x 1.6 cm is observed, dependent on skin and with infiltration to subcutaneous cellular tissue.*



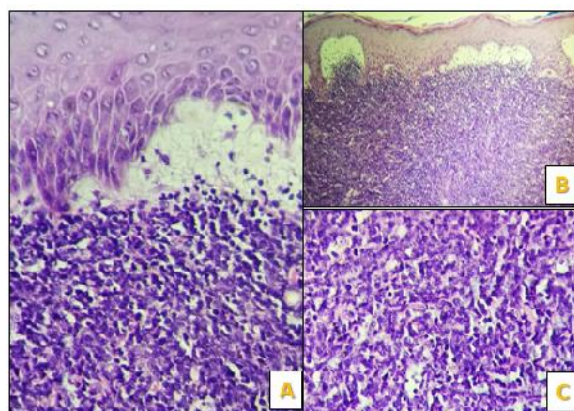
*Fig.3 Complete surgical resection of the lesion at the level of the left iliac fossa.*

## Discussion

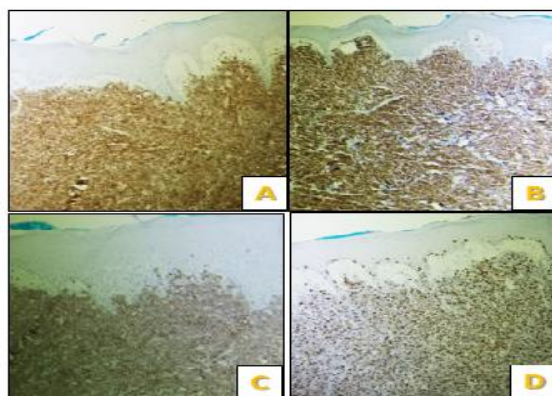
Non-Hodgkin Lymphoma Between 1975 and 2010, childhood cancer mortality decreased by more than 50% .6,7For non-Hodgkin's lymphoma (NHL), the 5-year survival rate increased during the same period from 45 to 87% in children under 15 years of age and from 48 to 82% in adolescents aged 15 to 19 years. NHL is very rare in infants (1% in the BFM trials from

1986 to 2002) .3 In a retrospective review, the outcome for infants was more precarious compared to older patients with NHL seems to be worse in pediatric patients with diffuse large B-cell lymphoma and chromosomal rearrangement of MYC (8q24).<sup>8</sup>

Like Burkitt's lymphoma or leukemia or similar to the Burkitt type, current treatment strategies are based on risk classification.



*Fig. 4 Histological section of the lesión where A is observed. – The respected dermoepidermal junction, B). - In the panoramic view (10x) the large cell lymphoid neoplasm and diffuse growth pattern is seen, C) .- There is atypia and apototic bodies that reflect*



*Fig.5 Immunohistochemical staining showing positivity for B lymphoid markers, PAX5 (A), CD10 (B), as well as expression of CD43 (C) and Ki67 that reflects a high proliferation index (D).*

## Conclusion

The diffuse LNH of mature B cells is of the neoplasms with lower incidence in the pediatric population younger than 5 years, with a worse prognosis in comparison with adolescents and adults, being of vital importance an early diagnosis with effective staging to offer a greater survival to the patients with this pathology.

## Bibliografia

1. Ries L a. G, Smith M a., Gurney JG, et al. Cancer incidence and survival among children and adolescents: United States SEER Program 1975-1995. *NIH Pub No 99-4649*. 1999:179 pp.
2. Kempf W, Kazakov D V., Belousova IE, Mitteldorf C, Kerl K. Paediatric cutaneous lymphomas: A review and comparison with adult counterparts. *J Eur Acad Dermatology Venereol*. 2015;29(9):1696-1709. doi:10.1111/jdv.13044
3. Mann G, Attarbaschi A, Burkhardt B, et al. Clinical characteristics and treatment outcome of infants with non-Hodgkin lymphoma. *Br J Haematol*. 2007;139(3):443-449. doi:10.1111/j.1365-2141.2007.06796.x
4. Mbulaiteye SM, Biggar RJ, Bhatia K, Linet MS, Devesa SS. Sporadic childhood Burkitt lymphoma incidence in the United States during 1992-2005. *Pediatr Blood Cancer*. 2009;53(3):366-370. doi:10.1002/pbc.22047
5. Progress M. CHILDHOOD. 1996:1238-1248.
6. Smith MA, Ltekruse SF, Adamson PC, Reaman GH, Seibel NL. Declining Childhood and Adolescent Cancer Mortality. *Cancer*. 2014;120(16):2497-2506. doi:10.1002/cncr.28748. Declining
7. Karalexi MA, Georgakis MK, Dessypris N, et al. Mortality and survival patterns of childhood lymphomas: geographic and age-specific patterns in Southern-Eastern European and SEER/US registration data. *Hematol Oncol*. 2017;35(4):608-618. doi:10.1002/hon.2347
8. Genetics H, Transplantation M, Presbyterian NY, et al. HHS Public Access. 2010;23(December 2003):323-331. doi:10.1038/leu.2008.312.

Access this Article in Online	
	Website: <a href="http://www.ijarm.com">www.ijarm.com</a>
	Subject: Medical Sciences
Quick Response Code	
DOI: <a href="https://doi.org/10.22192/ijamr.2018.05.10.002">10.22192/ijamr.2018.05.10.002</a>	

### How to cite this article:

J.A. Román Franco, P. GonzálezGalván, R.E. Salgado Sangri, G. Esquivel Martinez, M.A. Murillo, D.Piedras González. (2018). Non-Hodgkin's Large B-cell Non-Hodgkin Lymphoma with skin infiltration in a nursing patient. Case Report and Literature Review. *Int. J. Adv. Multidiscip. Res.* 5(10): 7-11.  
DOI: <http://dx.doi.org/10.22192/ijamr.2018.05.10.002>