

Case Report

SOI: <http://s-o-i.org/1.15/ijarm-2016-3-2-14>

A case report of Amphistomiasis in sheep

Amaravathi M^{1*}, Bharath Kumar Reddy C² and Nagendra Reddy M³

Veterinary Dispensary, Kadapa - 516193

¹Ph.D Scholar, Department of Veterinary Pathology, C.V.Sc, Tirupati

² Ph.D Scholar, Department of Veterinary Medicine, C.V.Sc, Tirupati.

³Veterinary Assistant Surgeon, Porumamilla, Kadapa

*Corresponding Author: ammu.nihal@gmail.com

Keywords

Amphistomiasis,
operculated eggs,
rumen and sheep.

Abstract

This case report describes amphistomiasis in sheep caused by *Paramphistomum* sp. Two carcasses were presented for the post mortem examination with the history of persistent foetid diarrhoea, emaciation and sudden death. Faecal examination revealed operculated eggs with yolk and germ cells in the intestinal contents. Grossly, severe amphistome parasites were observed in the rumen and in reticulum also few amphistomes were present.

Introduction

Paramphistomes are commonly occurring trematodes infecting various domestic ruminants in India. It has a wide geographical distribution in subtropical and tropical areas, where the infection leads to economic losses related to mortality, poor health condition, retarded growth and low productivity (Kilani et al. 2003). In ruminants, paramphistomiasis has been found to be associated with diarrhoea, loss of body condition, rough hair coat, dullness, weakness, loss of appetite, intestinal haemorrhages, anaemia and intermandibular swelling (Chandrasekharan et al. 1982 and Blood et al. 1983).

Materials and Methods

Investigation was taken up to find out the cause of death in two sheep that were presented to Veterinary Dispensary, Kadapa district, Andhra Pradesh. Faecal samples analysis was done by faecal floatation and sedimentation techniques. To enhance the visibility, a drop of Lugol's Iodine was added to the slide before examination. The rumen and reticulum were collected and fixed in 10 % neutral buffered formalin.

Results and Discussion

Grossly, numerous pink parasites were attached to the ruminal papillae (Fig. 1 & 2) and reticulum (Fig. 3). During faecal

examination, operculated eggs with yolk and germ cells were observed (Fig. 4) and no other helminthic infection was observed in these two cases. Microscopically, there was mild to moderate infiltration of mononuclear cells and few eosinophils in lamina propria. Similar findings were also observed by Uddin et al. (2006) and Ozdal et al. (2010)

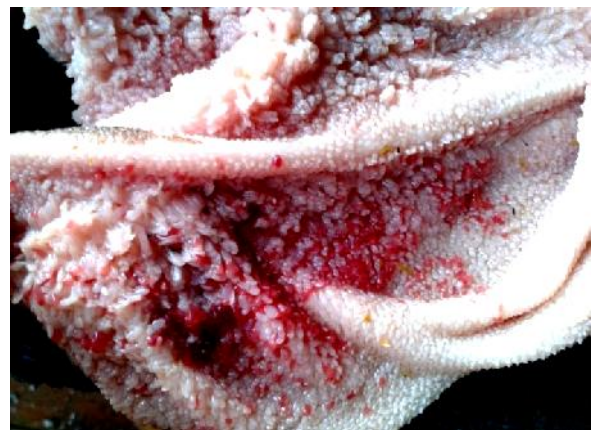

Figure .1

References

1. Ahmad, T., Reshi, M. L., Chesti, M. Z, Tanveer, S. and Shah, Z. A. 2013. A case report of *Gastrothylax crumenifer* incidence in sheep in Kashmir Valley. Iraqi Journal of Veterinary Sciences. Vol. 27, No. 1 :71-72
2. Blood, D. C., Radostits, O. M. and Henderson, J. A. 1983. *Veterinary Medicine*. 6th edn., ELBS, Bailliere and Tindall, UK. pp. 906-907.
3. Chandrasekharan, K., Radhakrishnan, K. and Jacob, V. C. 1982. Efficacy of Distodin in the treatment of amphistomiasis in Indian elephants. *Kerala Journal of Veterinary Science*. 13: 55-58.
4. Kilani, K., Guillot, J. and Chermett, R. 2003. Amphistomes digestive. In: Lefevre P C, Blanco J, Chermatt J (Eds.), *Principales maladies infectieuses et parasitaires du betail*. (1st Edn.), Paris. Tec. and Doc. PP: 1400-1410.
5. Ozdal, N., Gul, A., Ilhan, F. and Deger, S. 2010. Prevalence of *Paramphistomum* infection in cattle and sheep in Van Province, Turkey. *HELMINTHOLOGIA*. 47 (1): 20 – 24.
6. Uddin, M. Z., Farjana, T., Begum, N. and Mondal, M. M. H. 2006. Prevalence of amphistomes in black bengal goats in mymensingh district. *Bangl. J. Vet. Med.* 4 (2): 103–106.

Access this Article in Online



Website:

www.ijarm.com

Subject:

**Veterinary
Pathology**

Quick Response Code

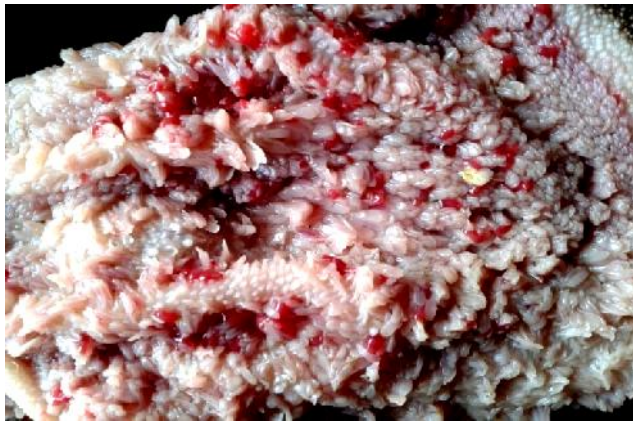


Figure 2.

Fig. 1 & 2 Note numerous pink amphistomes attached to ruminal papillae

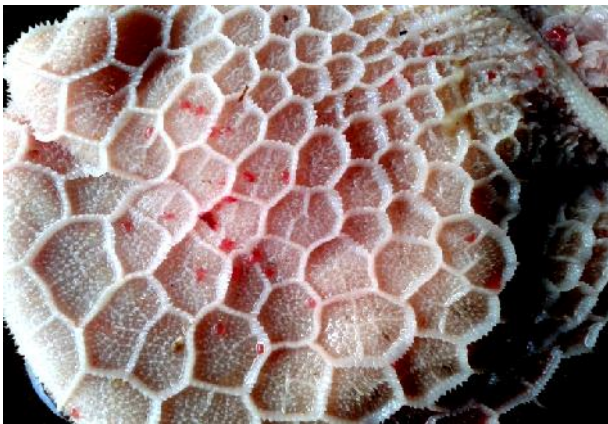

Fig. 3 Note few amphistomes in reticulum



Fig. 4 Note presence of operculated eggs in faecal sample

Conclusion

The present study concludes that sheep are susceptible to amphistome infection and further investigation is needed to focus on control procedures of amphistomes infection in sheep.

How to cite this article:

Amaravathi M, Bharath Kumar Reddy C and Nagendra Reddy M. (2016). A case report of Amphistomiasis in sheep. *Int. J. Adv. Multidiscip. Res.* 3(2): 92-93.