

The effect of Hyperbaric Oxygen in Bone Regeneration cells

^a**Leticia Lara Jiménez**, Resident Doctor

^b**Julio César Ramírez Nava**, Medical Specialist

^c**Félix Guillermo Márquez Celedonio**, Master in Science

^d**Zahir García Torres**, Medical Specialist

^e**Josué Elí Villegas Domínguez**, Master in Science

^f**Juan Antonio Moreno Luna**, Medical Specialist

^g**Karime Guadalupe Cárdenas Ureña**, Medical Specialist

^h**Gabriela Patricia Romero Bayardo**

^aHealth Service Naval Graduate School, Naval Specialty Hospital of Veracruz, México. TTE NAV SSN MCN, third-year resident Physician. E-mail: zamy2604@gmail.com

^b Naval Specialty Hospital of Veracruz, México. CAP FRAG SSN MCN, Hyperbaric and Undersea Medical Specialist. E-mail: smarnav@hotmail.com

^cResearch and investigation Coordinator, Health Science Academy, Universidad del Valle de México campus Veracruz, México. Master in Clinical Research. E-mail: felix.marquez@uvmnet.edu.mx

^dOral and Maxillofacial Surgery Department, Naval Specialty Hospital of Veracruz, México. TTE FRAG SSN CD, Cirujano Maxilofacial / Facultad de Odontología, Universidad del Valle de México, campus Veracruz. E-mail: zahir_garcia@my.uvm.edu.mx

^eHealth Service Naval Graduate School, Naval Specialty Hospital of Veracruz, México / School of Medicine “Dr. Porfirio Sosa Zárate”, Universidad del Valle de México, campus Veracruz, México. Master in Clinical Research. E-mail: josue.villegas@uvmnet.edu.mx

^fPathologic Anatomy Department, Naval Specialty Hospital of Veracruz, México. CAP FRAG SSN MC Médico patólogo. E-mail: morenoluna73@hotmail.com

^gHealth Service Naval Graduate School, Naval Specialty Hospital of Veracruz, México. TTE NAV SSN MCN, Hyperbaric and Undersea Medical Specialist. E-mail: axo603@hotmail.com

^hSchool of Medicine “Dr. Porfirio Sosa Zárate”, Universidad del Valle de México, campus Veracruz. E-mail: gabrielabayardo@gmail.com

Corresponding Author: Leticia Lara Jiménez

Yaxcopoil Street, Mzn 148, Lt 8 Between Saxan and Nizuc, Zip Code 77086

CR 77001, Colonia Solidaridad, Chetumal, Quintana Roo, México

Correo electrónico: zamy2604@gmail.com

Abstract

Keywords

hyperbaric oxygen,
remodeling of bone
tissue,
remodeling bone cells

Background and objectives: Hyperbaric oxygen has proven to increase angiogenesis and remodeling of bone tissue; the objective of the study is to determine the effect it has on the cells involved in the process of bone regeneration.

Material and methods: An experimental study administrating hyperbaric oxygen therapy to patients with jaw fractures. The percentage by mm^2 on fibroblasts, osteoblasts, osteocytes and osteoclasts was measured, and a descriptive statistic and inferential analysis was made.

Results: Seventeen (56.7%) patients were submitted to the experimental intervention. The initial count of fibroblasts was 9.7 ± 13.7 and 30.5 ± 20.8 final ($p = .0003$), osteoblasts 3.4 ± 2.8 initial and 29.5 ± 19.7 final ($p = .0003$), osteocytes 13.4 ± 9.7 basal and 57.6 ± 19.9 final ($p = .0004$), osteoclasts 0.1 ± 0.3 basal and 2.7 ± 1.7 final ($p = .0004$).

Conclusions: The amount of fibroblasts, osteoblasts, osteocytes and osteoclasts was higher with the administration of hyperbaric oxygen than the expected with conventional therapy.

Introduction

Hyperbaric oxygen therapy (HBOT) has been used by the Undersea & Hyperbaric Medical Society (UHMS) as an “intervention in which an individual breathes near 100% oxygen intermittently while inside a hyperbaric chamber that is pressurized higher than sea level pressure” (Weaver LK, 2014). Its effects have been observed in cellular or tissue level and are determined by volumetric and solumetric effects conditioned by a high pressure and breathing pure oxygen, which increases the partial pressure of oxygen the individual is breathing; these effects are explained in the law of Boyle-Mariotte and Henry (Castellanos-Navarro JM et al, 2006; Iriarte-Otobe JI et al, 2006).

The solumetric effect improves tissue hypoxia, cicatrization is stimulated, and the angiogenesis and immune response are upgraded; meanwhile volumetric effect takes part with gas embolism and vasoconstriction without compromising the oxygen saturation. Both processes ameliorate bone tissue and fibroblasts proliferation, neovascularization, mineralizing and regulates osteoclastic and osteoblastic function; these are closely related to bone formation, remodeling, and necrotic tissue removal (Tapia-Gallardo Het al, 2015; Thom SR, 2011; Torres-León JM et al, 2015).

The HBOT has been applied in numerous pathologies; during the 10th European Consensus Conference on Hyperbaric Medicine, it was established as a recommendation with evidence Type 1 or strongly recommended its use in open fractures with crush injury, prevention of osteoradionecrosis after dental extraction and osteoradionecrosis in mandible.

In addition, it was established that with HBOT there is not only a palliative effect, but also a healing effect in wounds secondary to oncological radiotherapy, which helps to deal with other clinical conditions (Ceponis P et al, 2017; Desola J, 2017; Re K et al, 2019). In patients with a high risk of developing osteoradionecrosis after a dental extraction, HBOT reduced loss of continuity in the mandible; likewise, patients with radial or ulnar fracture improved their functional capacity and recovery time and symptoms diminished (Mathieu D et al 2017).

The first evidences of bone regeneration with HBOT were attributed to Nilsson et al (1988), whom documented significant increase in generation and growth of lamellar bone in the proximal region of metaphyseal bone in the tibia of rabbits exposed to HBOT. Subsequently, Grassmann JP et al (2015) exhibited in an experimental group of rabbits, an increase of angiogenesis, intraosseous microvascular density and larger volume of the new bone created, than the control group that wasn't treated with HBOT. There is no mayor evidence of the effect of HBOT in bone regeneration in fractures; mandible fractures are traumatic injuries in which there is loss of continuity in the mandibular bone, through a bone gap, and its incidence and epidemiologic characteristics vary according to geographic conditioning factors and demography; in a lot of countries, it has been reported that these fractures are among the first ten most common fractures of the whole body and in the second place of facial fractures (González de Santiago MJ et al, 2017; Lanás G et al, 2019; Morales-Navarro D, 2017; Zavlin D et al, 2018;). The purpose of this research is to determine through an experimental study the effect of HBOT in bone regeneration in mandible

fractures in humans through quantification of fibroblasts, osteoblasts, osteoclasts and osteocytes increment.

Materials and Methods

An experimental study was carried out in individuals with simple mandible fracture which were treated in the services of the maxillofacial surgery and the Hyperbaric and Subaquatic medicine departments in the Naval Specialty Hospital of Veracruz SEMAR from March 2019 to October of the same year; patients had to accomplish the requirements to be part of the study which meant they had to have no other ailments that could contraindicate the HBOT treatment, sign an informed consent letter, receive the HBOT and get a biopsy taken. Likewise, the protocol was submitted to assessment and approved by the research and ethics committee of the institution.

The patients that participated in the study were scheduled for an open reduction and internal fixation of the mandibular fracture and afterwards got an explanation about the HBOT, and its potential risks and benefits; they received the established treatment for this type of injury which consists of surgical approach of the mandible fracture followed by the routine protocol of neurological assessment, head and neck physical exploration and a computed axial tomography.

After asepsis and antisepsis, an interdental fixation in the maxillary was effectuated to obtain centric occlusion and after that, the surgical approach for the biopsy in the mandible with an initial 3 mm sample of bone located in the same trace. The surgical procedures were performed under general anesthesia balanced with a nasotracheal intubation.

Posterior to the surgical procedures, the patients who participated were put through 20 sessions of HBOT during 5 days (from Mondays to Fridays), which lasted 60 min each breathing 100% O₂ with a pressure of 2.5 ATA'S (245.16 kPa) through an on-demand consumer system with an Amron® brand "second stage" valve and a facial mask.

The HBOT administration took place in a multiplace hyperbaric chamber with two cylindrical, human occupation compartments, which measured 1950 mm x 4880 mm long, from a Mexican manufacturer brand Patrupa Industrial S.A. de C.V. which accomplishes the norms of the *American Society of Mechanical*

Engineers (ASME) Section VIII, Division 1, Edition 2013; this chamber has an auxiliary equipment with two screw compressors Kaeser brand (Sigma model from a German manufacturer) and two reservoirs, boilers of 500 liters each and a line filter with 3 multilayer filters of local development. The oxygen is obtained from the hospital supply which has a stationary tank type thermo cryogenic provided regularly by commercial liquid oxygen.

Once the 20 sessions with HBOT took place, a new incisional biopsy under local anesthesia was taken; with a lidocaine HCL 2% and epinephrine injection and then fibroblasts, osteoblasts, osteocytes and osteoclasts were quantified. The obtained biopsies were processed for their microscopic description through a decalcification with nitric acid, buffered formaldehyde for fixation, paraffin-wax embedding, and haematoxylin and eosin stain. Finally, a microscope with conventional light and 10x and 40x objective lens to assess bone structure, its remodeling stage and quantification of regeneration bone cells per sample.

The analysis plan of the study included descriptive statistics with absolute and relative (%) frequencies by estimation, central tendency calculation of measures and dispersion measures, and the statistic inference through the application of Yate's correction in Chi test, Fisher's exact test, Wilcoxon rank sum test or t Student test for paired samples according to the characteristics of the variables and accomplishment of statistical requirements for the use of parametrical tests. The significance level for the null hypothesis rejection was set at 0.05.

Results

In the studio, 17 (56.7%) patients were included; the characteristics of the studied population were in an age range of 33.3 ± 11.1 year, 18 (58.8%) were female and 7 (41.2%) were male, 6 (35.3%) had occupation as active marine subjects, 9 (52.9%) were beneficiaries, 1 (5.9%) was a cadet, and 1 (5.9%) was a retired marine. In 7 (41.5%) of the total patients the cause of the mandible fracture was a car accident, 2 (11.8%) were by physical aggression, 2 (11.8%) were work accident, 2 (11.8%) had a pathological etiology (Table 1).

Table 1
Features socio demographic and etiology of fracture in conventional treatment y HBOT patients
N=17

Age (median and SD)	33.3 ± 11.1
Gender	
Female	10 (58.8%)
Male	7 (41.2%)
Occupation	
Active Marine	6 (35.3%)
Beneficiary	9 (52.9%)
Cadet	1 (5.9%)
Retired marine	1 (5.9%)
Fracture etiology	
Car crash	7 (41.2%)
Physical aggression	2 (11.8%)
Work accident	2 (11.8%)
Pathological ethiology	2 (11.8%)
Fall	2 (11.8%)
Sports related	2 (11.8%)

Values expressed in absolute frequencies and percentage except the age

Source: Own elaboration

The quantitative analysis of the regeneration bone cells in the group of patients with conventional treatment and HBOT cameup with a count of 9.7 ± 13.7 fibroblasts in the first counting and 30.5 ± 20.8 at the end of the 20 sessions of HBOT ($p = .0003$), osteoblasts were 3.4 ± 2.8 at first and 29.5 ± 19.7 at the end ($p = .0003$), osteocytes were 13.4 ± 9.7 in the basal measure and 57.6 ± 19.9 finally ($p = .0004$), osteoclasts were 0.1 ± 0.3 and 2.7 ± 1.7 basal and final measure respectively ($p = .0004$); the increment in the

percentages of the regeneration bone cells were 213.9%, 780.7%, 329.8% and 2200.0% respectively. (Table 2, Fig. 1, 2, 3, and 4).

Additionally, the pain evolution was assessed through a Visual Analogue Scale obtaining a median score of 4 (range 4 to 5) in the basal measure of the experimental intervention and a median of 1 (range 1 to 2) in the final measure ($p=.0003$).

Table 2
Comparison of basal and final quantities of bone regeneration cells in conventional treatment and hyperbaric oxygen therapy
N=17

	Basal	Final	p Value
Fibroblasts	9.7 ± 13.7	30.5 ± 20.8	0.0003
Osteoblasts	3.4 ± 2.8	29.5 ± 19.7	0.0003
Osteocytes	13.4 ± 9.7	57.6 ± 19.9	0.0004
Osteoclasts	0.1 ± 0.3	2.7 ± 1.7	0.0004

Values expressed in median ± standard deviation

p Values obtained from ranges and signs test of Wilcoxon

Source: Own elaboration

Fig. 1
Comparison of fibroblasts quantity basal and final in patients with fracture and hyperbaric oxygen therapy

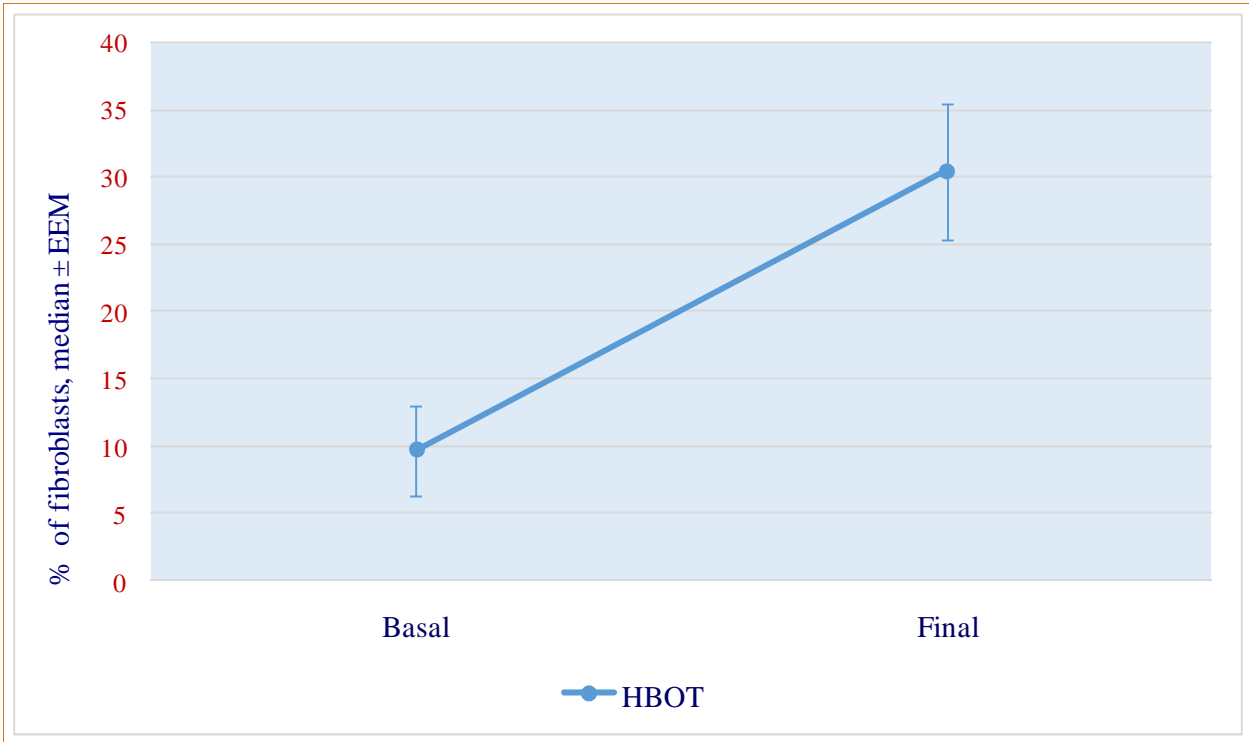


Fig. 2
Comparison of osteoblasts quantity evolution in patients with fractures and hyperbaric oxygen therapy

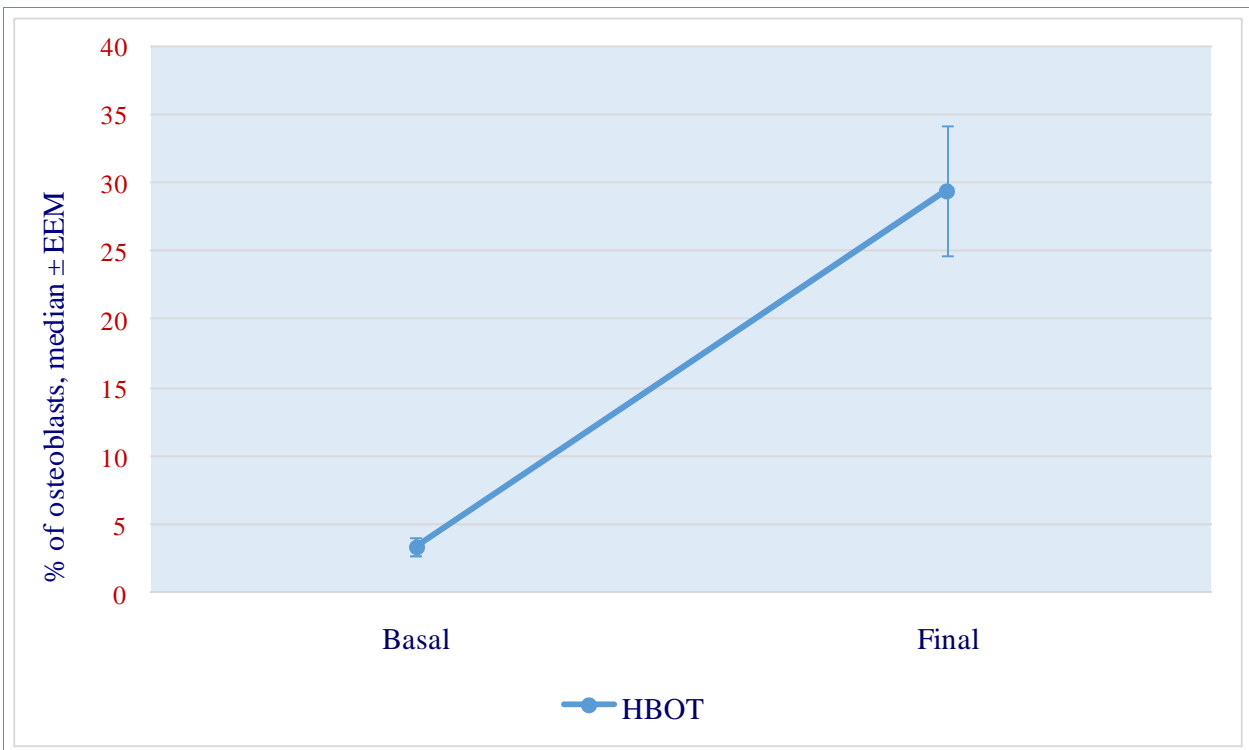


Fig. 3
Comparison of osteocytes quantity evolution of patients with fracture and hyperbaric oxygen therapy

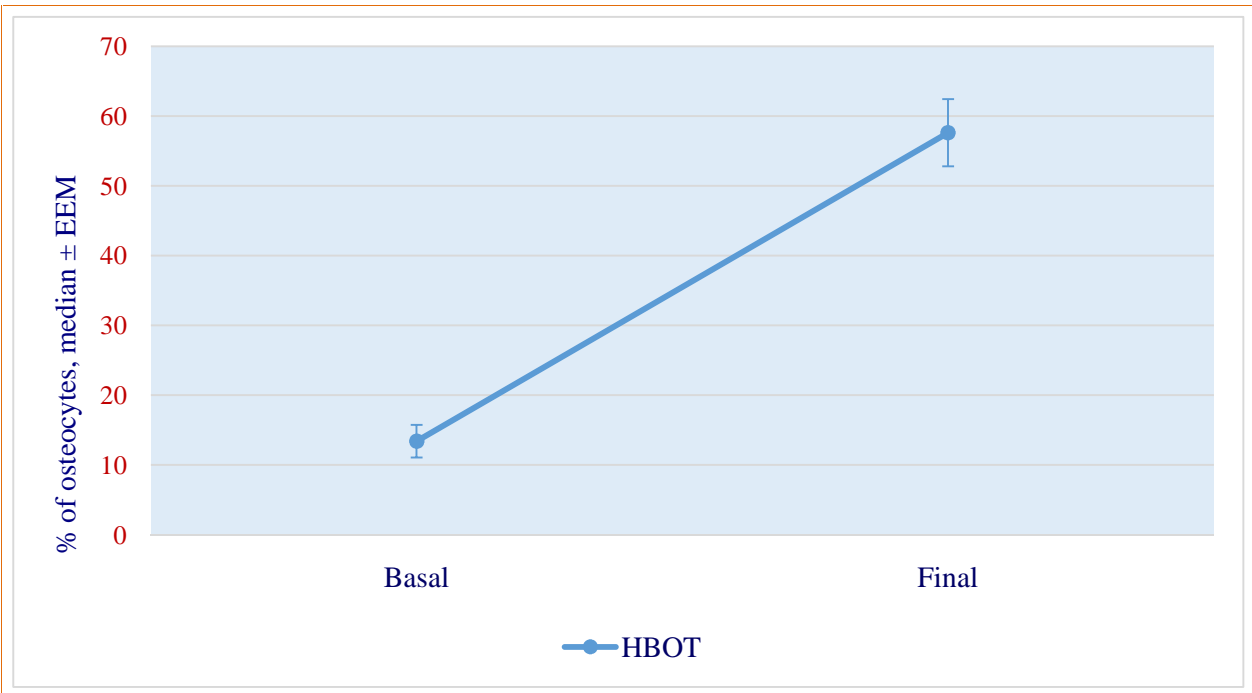
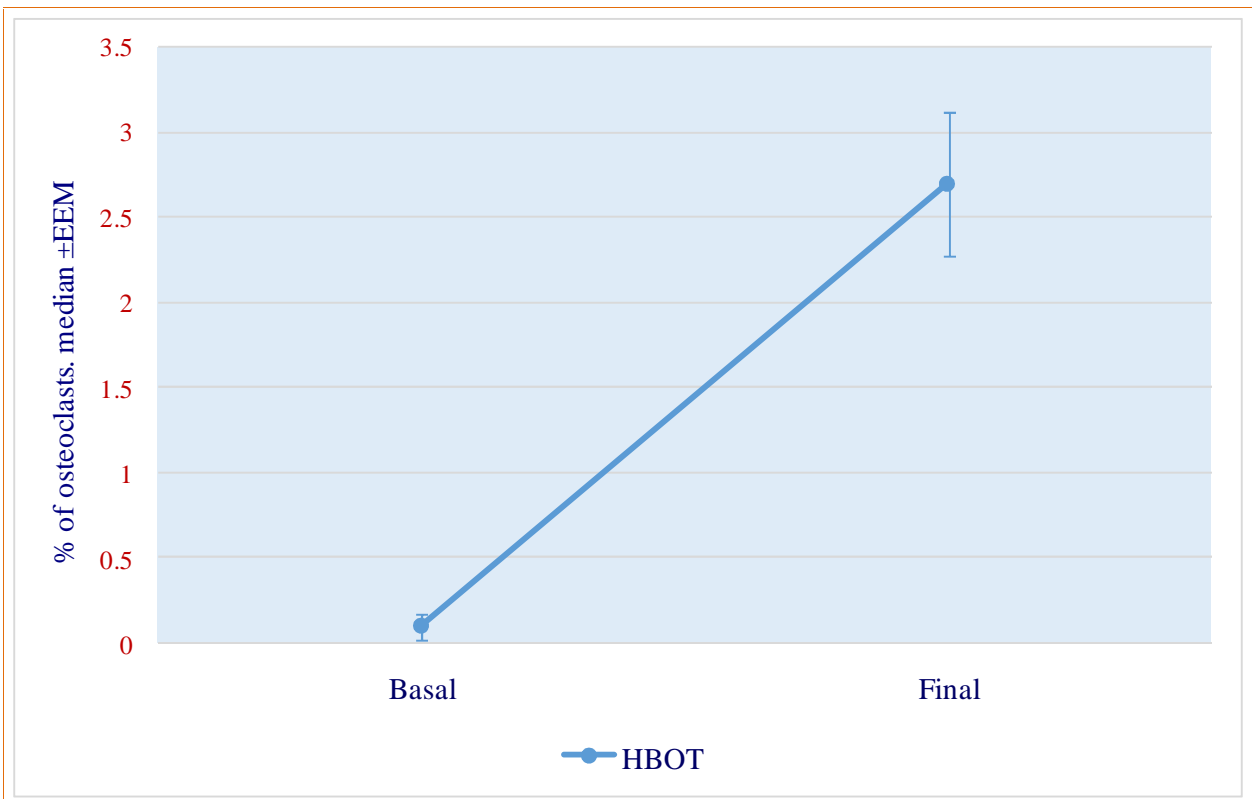


Fig. 4
Comparison of osteoclasts quantity evolution in patients with fractures and hyperbaric oxygen therapy



Discussion

The findings in our study showed a statistically significant increment of the regeneration bone cells with conventional treatment and HBOT which coincidentally with the hypothesis prediction of the investigators, the exposition of the patients to 100% oxygen to 2.5 ATAs in the hyperbaric chamber including the regular treatment reached an increased counting of fibroblasts, osteoblasts, osteocytes and osteoclasts after 20 sessions in contrary to the patients that only received conventional treatment; the counting of regeneration bone cells were from 151% for osteoclasts up to 374% for osteoblasts. These results in our study settle an establishment the notorious stimulating effect of HBOT in a physiological process such as bone regeneration in patients whom suffered mandible fractures.

The present study constitutes an experimental intervention pretest – retest with HBOT and conventional treatment; this methodologic procedure strengthens the obtained results; however, its weakness consists in quantifying the magnitude of the biologic effect obtained only by the exposition of patients to HBOT without considering meaningful clinical variants that permit to relate this effect with results of clinical interest for the medicine doctor and the patient, which should be approached in posterior studies. Furthermore, the realization of a randomized blinded trial would fortify the obtained results by comparing them concurrently with a group that were only exposed to simulated conditions to ambient oxygen.

In contrast with other published studies about the HBOT effects in regeneration bone cells that have taken place in animal models, our study exposed experimentally human beings. The studies of Grassman JP et al (2015) about the HBOT effect in the regeneration of bone defects in the radio diaphysis treated with autologous grafts in rabbits, demonstrated a similar significant improvement evaluated radiologic and histologically that was evident until 3 to 6 weeks of treatment with bone tissue formation from $24.3\% \pm 2.4\%$ in the central area of the injure and $26.2 \pm 2.5\%$ in the cortical area; this was statistically superior to the results from the group that didn't receive HBOT which was $14.1 \pm 3.3\%$ and $17.5 \pm 2.9\%$ in the central and cortical area respectively. The experience in the application of HBOT in fractures in human beings is limited; in 2012, Bennet MH et al, in a systematic review of trials about the use of HBOT to promote the consolidation of the fracture and treatment of not

consolidated fractures did not find clinical trials that accomplished the inclusion criteria in 122 published papers.

We conclude that the administration of HBOT and conventional treatment obtained and incremented quantity of fibroblasts, osteoblasts, osteocytes and osteoclasts that were higher than the expected with habitual management. This study reveals higher counting of bone regeneration cells in patients exposed to 20 sessions of Hyperbaric Oxygen Therapy.

Conflict of interests: None.

Funding source: This investigation has not received any specific funding from the public or commercial sectors and nonprofit.

References

- Bennet MH, Stanford R y Turner R. (2012) Hyperbaric oxygen therapy for promoting fracture healing and treating fracture non-union (Review). Cochrane Database of Systematic Review, 11, Art. No.: CD004712. DOI: 10.1002/14651858.CD004712.pub4.
- Castellanos-Navarro JM, Navarro-Navarro R, Chiriño-González A, Rodríguez-Alvárez JP (2006). Fracturas mandibulares. *Canarias Médica y Quirúrgica*, 4 (11): 19 – 27.
- Ceponis P, Keilman C, Guerry C, Freiburger JJ (2017). Hyperbaric oxygen therapy and osteonecrosis. *Oral Disease*, 23 (4): 141 – 151.
- Desola J (2017). Oxigenoterapia hiperbárica en el siglo XXI. Análisis crítico y reflexiones. *FMC*; 24 (3): 116 – 133.
- González de Santiago MJ, Alatorre-Pérez S, Silva-Suárez RA, Lastiri-Barrios JL. (2017). Incidencias de fracturas mandibulares. Revisión de 634 casos en 493 pacientes. *Revista Mexicana de Cirugía Bucal y Maxilofacial*, 13 (3): 95 – 99.
- Grassmann JP, Schneppebdahl J, Hakimi AR, Herten M, Betsch M, Lögters TT, Thelen S, et al (2015). Hyperbaric Oxygen Therapy Improves Angiogenesis and Bone Formation in Critical Sized Diaphyseal Defects. *J Orthop Res*, 33: 513 – 520. DOI10.1002/jor.22805
- Iriarte-Otobe JI, Batle-Vidal JM, Urdiain-Asensio M, Caubet-Biayna J, Morey-Mas MA, Collado-López J, et al (2006). Empleo de la oxigenoterapia mediante cámara hiperbárica en cirugía oral y maxilofacial. *Rev Esp Cir Oral y Maxilof*. 28 (1): 7 – 24

- Lanas G, Paredes F, Vallejo K, Lanas A, Zindel-Deboni MC (2019). Epidemiology and complications of facial fractures: a 5-year retrospective study. *Rev Fac Odontol Univ Antioq.* 30 (2): 191 – 201.
- Mathieu D, Marroni A, Kot J (2017). Tenth European Consensus Conference on Hyperbaric Medicine: recommendations for accepted and non-accepted clinical indications and practice of hyperbaric oxygen treatment. *Diving and Hyperbaric Medicine*, 47 (1): 24 – 32. doi: 10.28920/dhm47.1.24-32
- Morales-Navarro D (2017). Fractura Mandibular. *Revista Cubana de Estomatología*, 54 (3): 1 – 19.
- Nilsson P, Albrektsson T, Granström G, Röckert HOE (1988). The Effect of Hyperbaric Oxygen Treatment on Bone Regeneration: An Experimental Study Using the Bone Harvest Chamber in the Rabbit. *International Journal of Oral & Maxillofacial Implants*, 3 (1): 59 – 69.
- Re K, Patel Sh, Gandhi J, Suh Y, Reid I, Joshi G, et al (2019). Clinical utility of hyperbaric oxygen therapy in dentistry. *Med Gas Res.* 9 (2): 93 – 100. doi: 10.4103/2045-9912.260651
- Tapia-Gallardo H, Mancilla-Solorza E (2015). Efectos fisiológicos y terapéuticos de la oxigenación hiperbárica. *REEM*, 2 (1): 7 – 13
- Thom SR (2011). Hyperbaric oxygen – its mechanisms and efficacy. *Plast Reconstr Surg.* 127 (Suppl 1): 131S – 141S
- Torres-León JM, Domínguez-Alegría AR, Navarro-Téllez M, Brinquis-Crespo MA, Espigares-Correa A, Pérez-Mochales JF (2015). Patologías tratadas con oxigenoterapia hiperbárica en el Hospital Central de la Defensa. *Sanid mil.* 71 (2): 77 – 83.
- Weaver LK (2014). *Hyperbaric Oxygen Therapy Indications.* Undersea and Hyperbaric Medical Society, 13^a Edition, North Palm Beach.
- Zavlin D, Jubbal KT, Echo A, Izaddoost SA, Friedman JD, Olorunnipa (2018) O. Multi-institutional Analysis of Surgical Management and Outcomes of Mandibular Fracture Repair in Adults. *Cranial Maxillofac Trauma Reconstruction*, 11 (1): 041 – 048. DOI: 10.1055/s-0037-1603460

Access this Article in Online



Website:

www.ijarm.com

Subject:

Medical Sciences

Quick Response Code

DOI: [10.22192/ijamr.2020.07.12.002](https://doi.org/10.22192/ijamr.2020.07.12.002)

How to cite this article:

Leticia Lara Jiménez, Julio César Ramírez Nava, Félix Guillermo Márquez Celedonio, Zahir García Torres, Josué Elí Villegas Domínguez, Juan Antonio Moreno Luna, Karime Guadalupe Cárdenas Ureña, Gabriela Patricia Romero Bayardo. (2020). The effect of Hyperbaric Oxygen in Bone Regeneration cells. *Int. J. Adv. Multidiscip. Res.* 7(12): 6-13.

DOI: <http://dx.doi.org/10.22192/ijamr.2020.07.12.002>