

Case Report

DOI: <http://dx.doi.org/10.22192/ijamr.2018.05.04.010>

## "Diagnosis of Pulmonary Sequestration In Uterus"

Ana Laura Hernández<sup>1\*</sup>, Constantino Contreras V.<sup>2</sup>

<sup>1</sup>Radiology Resident at the Posgraduate School of Naval Sanity, Naval university and the Hospital General Naval de Alta Especialidad, Secretaría de Marina Armada de Mexico (SEMAR).

<sup>2</sup>Radiologist, Radiology Service of the Hospital General Naval de Alta Especialidad, Secretaria de Marina Armada de México (SEMAR), Mexico.

\*Correspondence: Dra. Ana Laura Hernández de la Cruz.

E-mail: [numancia\\_0@hotmail.com](mailto:numancia_0@hotmail.com)/[annyemi13@gmail.com](mailto:annyemi13@gmail.com)

### Abstract

#### Keywords

congenital anomaly,  
pulmonary  
sequestration,  
in utero.

Pulmonary sequestration is a rare congenital abnormality of the lung in which it is defined as an area of nonfunctional dysplastic lung tissue with an abnormal systemic blood supply. The incidence of congenital pulmonary malformations of the respiratory tract is 1 per 8,300 to 35,000, and pulmonary sequestrations compromise between 0.15% and 6.4% of congenital pulmonary malformations (1). The diagnosis is possible from the second trimester. Pulmonary sequestrants are classified according to their anatomical location, either intralobar or extralobar (2). Extralobar abductions are covered by a layer of visceral pleura and are completely separated from the operating areas of the lung; On the other hand, the intralobar kidnapped are not separated by a layer of pleura and are located within the normal lung tissue (2).

### Presentation of the case

The patient is a 28-year-old female patient, attended a prenatal check-up at our first-time hospital, reports having no significant medical history, or during pregnancy, an obstetric ultrasound is requested in which she reports a pregnancy of 24 SDG. attention in the report of the presence of a multicystic rounded image, with regular edges at the level of the right lung that conditions the heart's movement to the left, so that it is subsequently performed as complementary imaging studies, magnetic resonance and an echocardiogram. Estimated date of delivery estimated for August 1, 2018.

Fetal echocardiography was performed without findings of alterations in cardiac morphology.

During the magnetic resonance imaging, an artery that emerged from the lateral aspect of the abdominal aorta provides irrigation to the mass located in the lower lobe of the right lung, which corroborates the diagnosis of pulmonary sequestration.

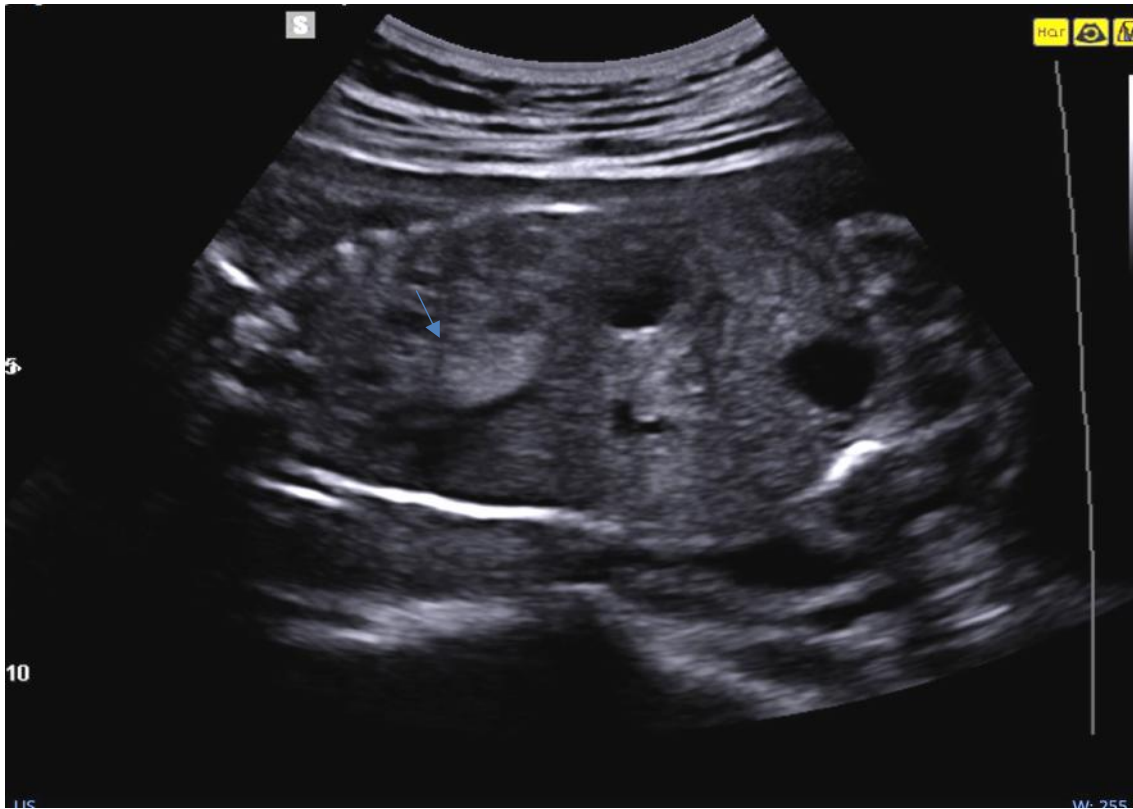


Figure 1: Prenatal ultrasound at 24 SDG in grayscale: Sagittal section showing echogenic image in the right lung (Arrow)

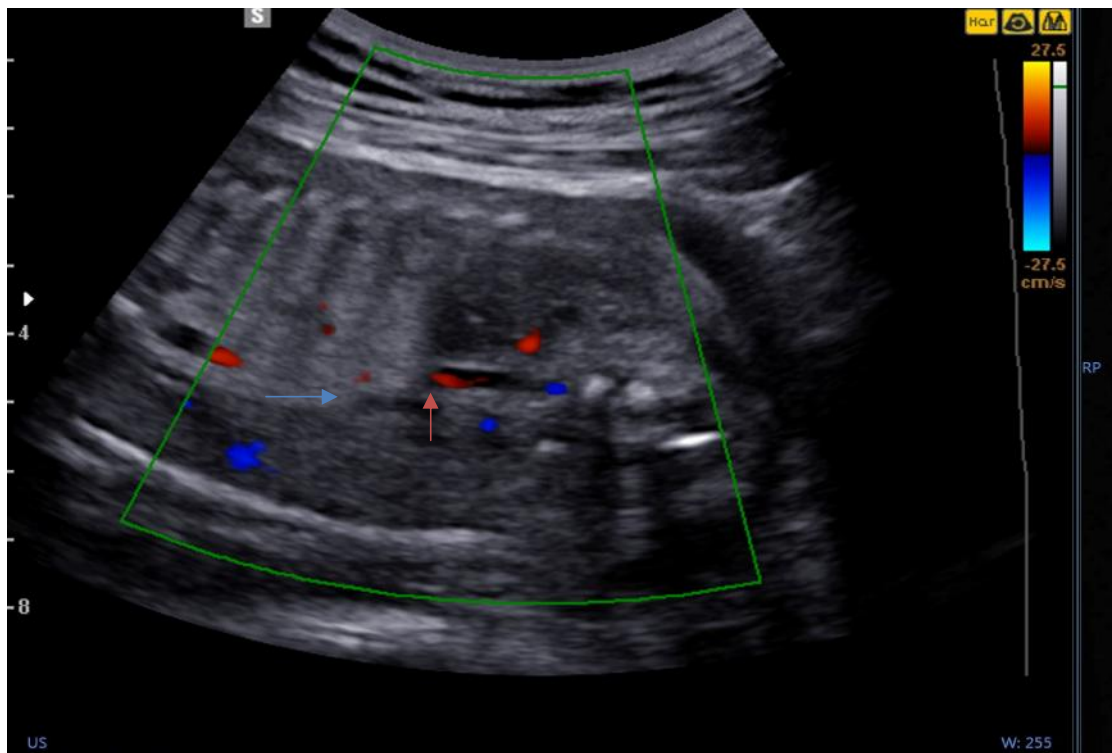


Figure 2: US prenatal color Doppler modality in which the vascularity of the pulmonary lesion from the aorta is observed (orange arrow).

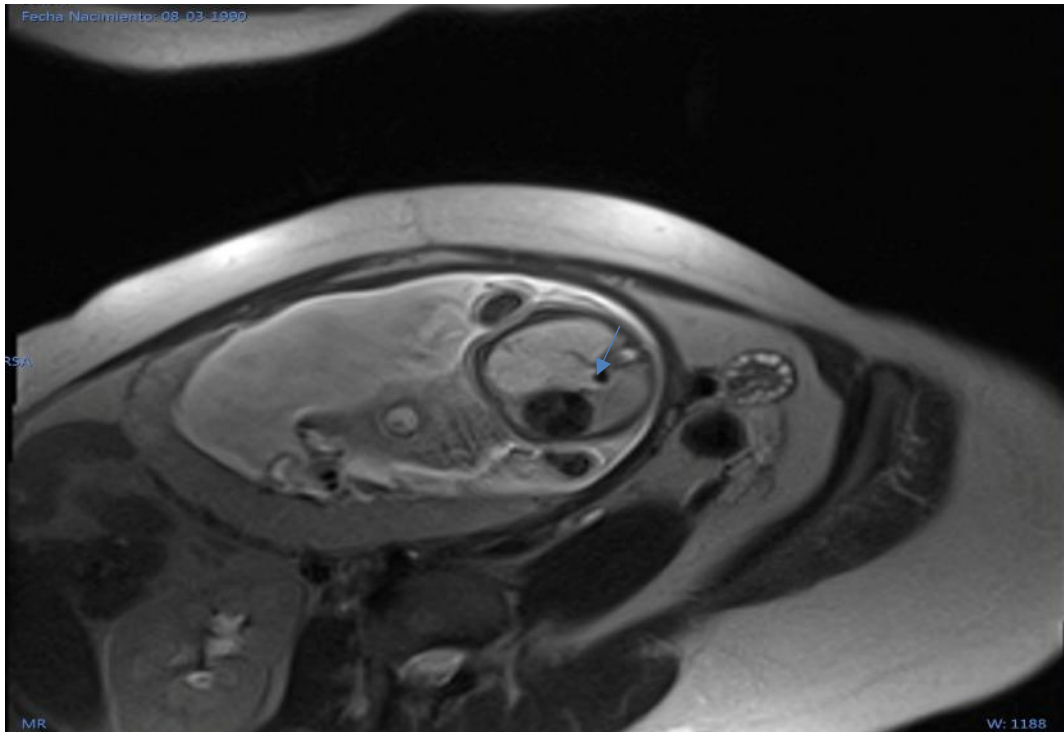


Figure 3: Prenatal MRI at 25 weeks, enhanced in T2, axial plane: in which hyperintense image is observed depending on the right lung and the arterial branch that supplies it with origin of the abdominal aorta (date).




Figure 4: T2-weighted MRI, sagittal plane: It is identified irregular hyperintense image essence of the right lung (arrow), without defining the cystic component.

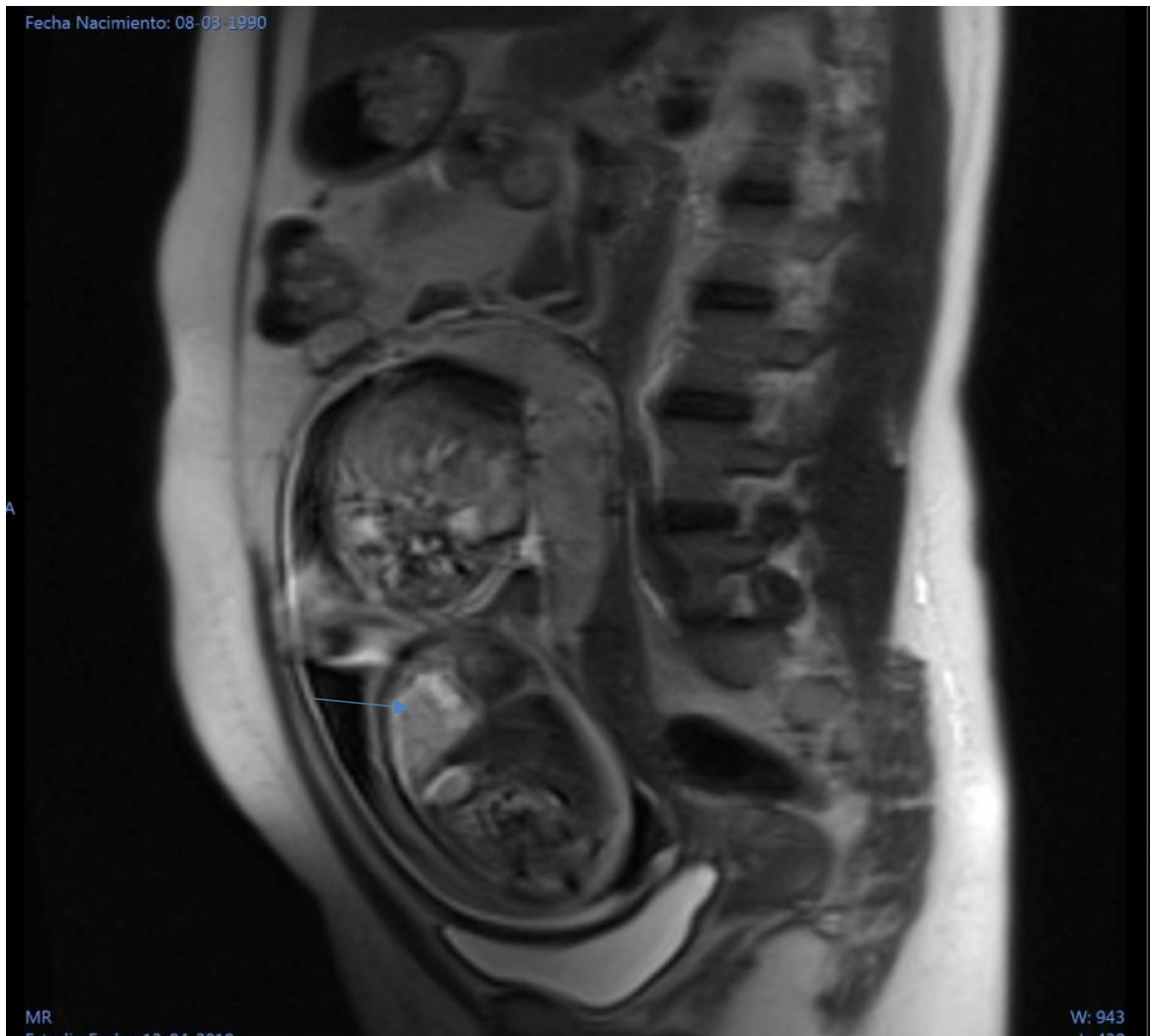


Figure 5: MR coronal hyperintense right lung mass that displaces the heart to the left.

## Discussion

The aberrant anomaly represents a segment of lung tissue with no connection to the tracheobronchial tree or the pulmonary arterial circulation (3). Pulmonary abductions are classified according to their anatomical location, either intralobar or extralobar (4), however prenatal diagnosis can be made by means of ultrasound where the utility of Doppler is reflected in the demonstration of the irrigation of the lesion, this

can also be verified with magnetic resonance, where it looks like a solid mass hyperintense in T2 sequence.

## Conclusion

As we already saw lung sequestration is usually a rare pathology, however the diagnosis can be made prenatally since we currently have imaging tools such as ultrasound and magnetic resonance, which allows us to evaluate the best treatment option for the newborn born.

## References

1. M. Nadeem , B. Elnazir , P. Greally **Malformación pulmonar congénita en niños** Scientifica, 2012 ( 2012 ) . Artículo ID 209896
2. CF Andrade, HPDC Ferreira , GB Fischer **Malformaciones pulmonares congénitas** J Bras Pneumol , 37 ( 2 ) ( 2011 ) , pp. 259 - 271
3. HE Aqrabawi **Secuestro pulmonar: reporte de un caso** J Clin Diagn Res , 1 ( 2007 ) , pp. 73 – 75
4. MM Chowdhury , S. Chakraborty **Imágenes de malformaciones pulmonares congénitas** Semin Pediatr Surg , 24 ( 4 ) ( 2015 ) , pp. 168 - 175

Access this Article in Online	
	Website: <a href="http://www.ijarm.com">www.ijarm.com</a>
	Subject: <a href="#">Medical Sciences</a>
Quick Response Code	
DOI: <a href="https://doi.org/10.22192/ijamr.2018.05.04.010">10.22192/ijamr.2018.05.04.010</a>	

### How to cite this article:

Ana Laura Hernández, Constantino Contreras V. (2018). Diagnosis of Pulmonary Sequestration In Uterus. Int. J. Adv. Multidiscip. Res. 5(4): 73-77.

DOI: <http://dx.doi.org/10.22192/ijamr.2018.05.04.010>