

International Journal of Advanced Multidisciplinary Research (IJAMR)

ISSN: 2393-8870

www.ijarm.com

Research Article

Treatment of periodontal bony defect with bovine derived xenograft and in combination of platelet rich Fibrin- A Case report

Gargi Shinde^a, Kaustubh P Patil^b, Vinayak D Kanakdande^c, Dr.Abhishek Singh Nayyar^{d*}

^aDepartment of Periodontics and Oral Implantology, Dr.D.Y.Patil Dental College & Hospital, Pune, Maharashtra, India

^bDepartment of Periodontics and Oral Implantology, Dr.D.Y.Patil Dental College & Hospital, Pune, Maharashtra, India

^cDepartment of Periodontics and Oral Implantology, Dr.D.Y.Patil Dental College & Hospital, Pune, Maharashtra, India

^dDepartment of Oral Medicine and Radiology, Saraswati-Dhanwantari Dental College and Hospital and Post-Graduate Research Institute, Parbhani, Maharashtra, India

*Corresponding Author

Abstract

Keywords

Platelet Rich Fibrin,
Bone graft,
Intra-bony defect,
Periodontal therapy

The aim of periodontal therapy is resolution of inflammation in the supporting structures of the tooth. Treatment of intra-bony defect has always been questionable. The present case report used a combination of PRF and bone graft in the treatment of a periodontal intra-bony defect with significantly improved clinical parameters. This procedure helps in saving a tooth which otherwise would have been deemed for extraction. Method: The present case report describes the combination use of PRF (platelet-rich fibrin) and bone graft in the treatment of a periodontal intra-bony defect. The tooth was root canal treated followed by periodontal therapy. A combination of PRF gel with xenograft was used to achieve faster healing of the intrabony defect. After 1 year, the absence of an intra-bony defect, pain and swelling along with tooth stability indicated a successful outcome. Conclusion: In this case report, combination of PRF and bone graft was used in the treatment of a periodontal intra-bony defect with significantly improved clinical parameters. The use of combination technique also promises additional benefit of rapid and early bone formation. One year follow-up results showed a reduction in gingival inflammation, tooth mobility and gain in attachment level.

Introduction

Periodontal disease is an inflammatory disease with differing levels of periodontal attachment loss and bone destruction. One of the objectives of periodontal therapy is the morphological and functional regeneration of lost periodontal supporting tissues. Periodontal regeneration requires a sequence of biological events including cell adhesion, migration, proliferation and differentiation.¹ Growth factors are a class of naturally occurring proteins involved in three key cellular events in tissue repair, mitogenesis, migration, matrix synthesis and remodelling.

Platelet-rich fibrin (PRF) described by Choukroun et al (2000)² is a second generation platelet concentrate which

allows one to obtain fibrin membranes enriched with platelets and growth factors, after starting from an anticoagulant-free blood harvest.^{3,4} PRF looks like a fibrin network and leads to more efficient cell migration and proliferation, and thus cicatrization.⁵ This unique structure may act as a vehicle for carrying cells that are essential for tissue regeneration. In addition, the PRF membrane could serve as a resorbable membrane for guided tissue regeneration. Many growth factors, such as platelet-derived growth factor (PDGF) and transforming growth factor- β (TGF- β), are released from PRF.^{3,4,6} Recently, studies have demonstrated that PRF membrane has a very significant slow sustained release of key growth factors for at least one week and up to 28 days, which

means that the membrane stimulates its environment for a significant time during wound healing.⁷ Some clinical applications have been described in oral surgery and implant dentistry.^{8,9} However, there are few references in the literature about the biological properties of PRF for periodontal intra-bony defects.^{5,4}

An anorganic Xenograft (Bio-Oss, Geistlich Pharma AG, Wolhusen, Switzerland) is a natural, porous, cancellous bone mineral derived from bovine bone from which all native organic material has been removed by a chemical low-heat extraction process maintaining the physical architecture of bone intact. Histologically, bone formation in humans with bovine bone mineral has been demonstrated in sinus elevation procedures,^{10,11} in alveolar ridge preservation/augmentation procedures,¹² around endosseous implants,¹³ and in periodontal bone defects^{14,15}. Clinically, the effectiveness of Bio-Oss xenograft in the reconstructive treatment of intra-osseous defects in humans has been evaluated when used alone.^{16,17,18}

Given the unique properties of autologous PRF and already demonstrated regenerative capacity of commercially available bone graft, application of a combination approach was attempted for the assessment of their additional benefits to the healing mechanism and periodontal regeneration. Herewith, we are presenting a one year follow-up report of an intra-bony defect treated by means of a combination of

autologous PRF with bovine derived xenograft assessed clinically with successful outcomes.

Case Report

A 24 year old male patient reported to the Department of Periodontology with a chief complaint of pain since 2 months in the upper right back tooth region. The nature of the pain was intermittent in nature. The patient used to take analgesics to relieve the pain. The patient was in good health and was a non-smoker. On examination, there was a periodontal abscess with respect to 16 region on the buccal gingival aspect. The enlargement was about 1x1cm in its greatest dimensions with well defined margins, pale pink in colour and had no sinus opening or active pus discharge. There was a deep periodontal pocket with respect to the mesial proximal aspect of 16 [Fig.1]. An intra-oral peri-apical radiograph (IOPAR) revealed an angular bone loss which was extending till the apical third of the root [Fig.2]. At the initial visit, the abscess was drained and patient was put on systemic antibiotics for five days and was asked to maintain the oral hygiene. On the second visit, thorough scaling and root planning was done. Vitality test was done on the tooth and the tooth was advised for an intentional root cal treatment. After three months, the patient was re-evaluated and the surgical treatment was scheduled. Routine blood investigations were advised that came-out to be normal.

Fig.1

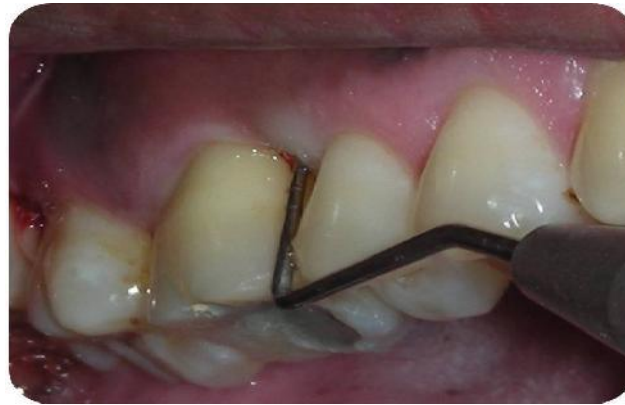
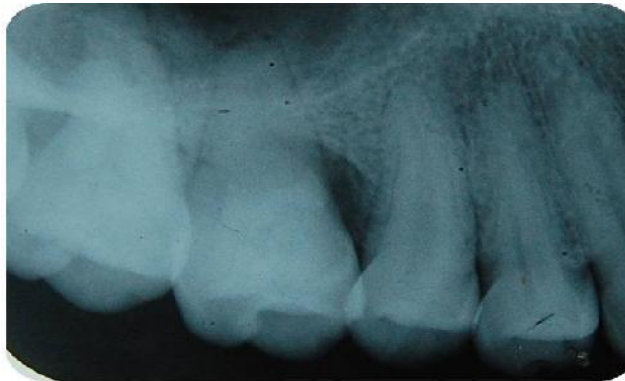
Fig.2



The use of Autologous PRF in combination with Xenograft (Bio-Oss) was advised for the treatment of the intra-bony defect. The surgical procedure consisted of the following steps:

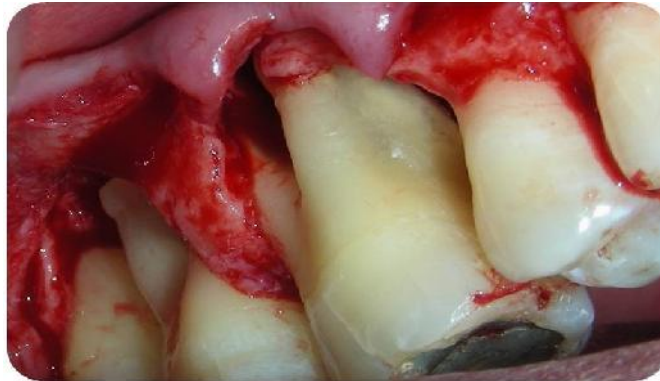
1. Preparation of PRF;
2. Open flap Debridement; and
3. Placement of PRF with BioOss in the bony defect.

Clinical pre-surgical measurements were recorded using a calibrated probe for the baseline values. An IOPAR was also taken prior to the start of treatment with a standardized paralleling cone technique.

Periodontal therapy

After 3 months, the patient was recalled for management of the intra-bony defect. After proper isolation of the surgical field, the surgical area was anaesthetised using 2% xylocaine hydrochloride with adrenaline (1:200000). Crevicular incisions were made using a Bard–Parker No.15 blade (BD, Franklin Lakes, NJ, USA) on the facial and lingual surfaces of the offending tooth with one adjacent tooth on either side. A full-thickness mucoperiosteal flap was reflected using a periosteal elevator. The defect was thoroughly debrided and the root surface was then planed and the flap trimmed to remove granulation tissue tags and minimise bleeding [Fig. 3]. This was followed by irrigation with Betadine® (Purdue Products, Stamford, CT, USA) and sterile saline solution.

Fig.3



PRF preparation

The advantages of PRF over PRP are its simplified preparation and lack of biochemical handling of the blood. A blood sample of the patient was drawn in 10 mL test

tubes without an anticoagulant [Fig.4] and centrifuged immediately. Blood was centrifuged using a tabletop centrifuge (REMY Laboratories, Chennai, Tamilnadu, India) for 12 min at 3000 rpm [Fig.5]. The resultant product consisted of the following three layers [Fig.6,7]:

Fig.4

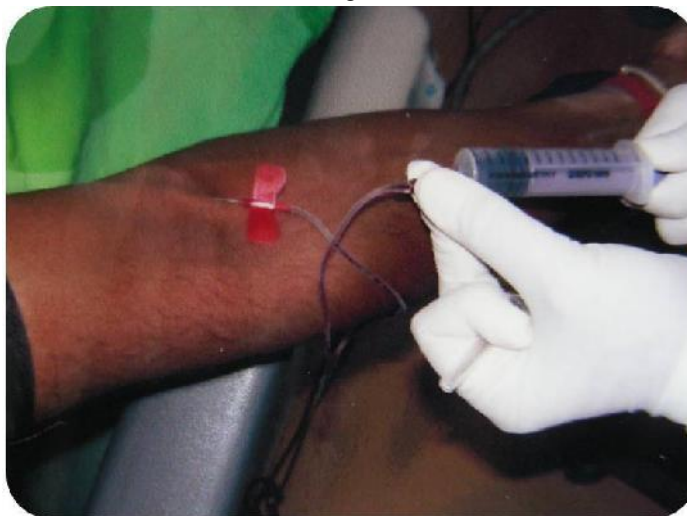


Fig.5




Fig.6


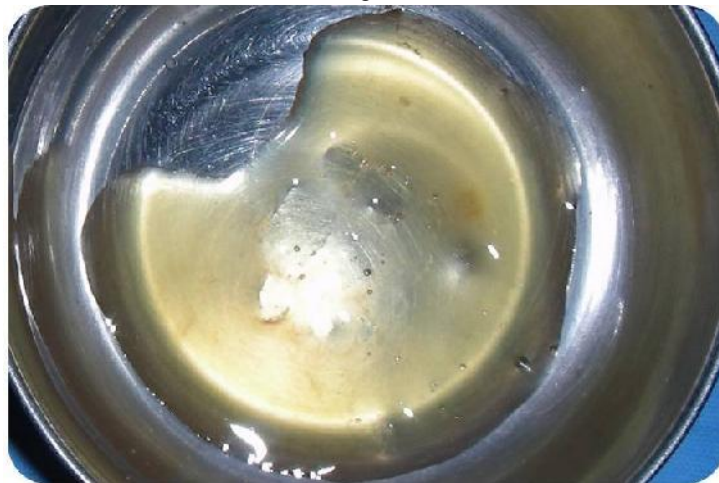


Fig.7



- the upper layer of acellular PRF plate or plasma may
- PRF clot in the middle; and
- red blood cells at the bottom.

Because of the absence of an anticoagulant, blood begins to coagulate as soon as it comes in contact with the glass surface. Therefore, for successful preparation of PRF, speedy blood collection and immediate centrifugation, before the clotting cascade is initiated, is absolutely

essential. The PRF is obtained in the form of a membrane by squeezing out the fluids in the fibrin clot. After debridement, bovine derived xenograft (BioOss) was mixed with the PRF gel derivative in a sterile dappen dish to a paste-like consistency [Fig.8]. This was placed into the periodontal defects to the level of the surrounding bony walls taking care not to overfill [Fig.9]. It has been suggested that under-filling or over-filling may be counter-productive because it may preclude proper flap.

Fig.8

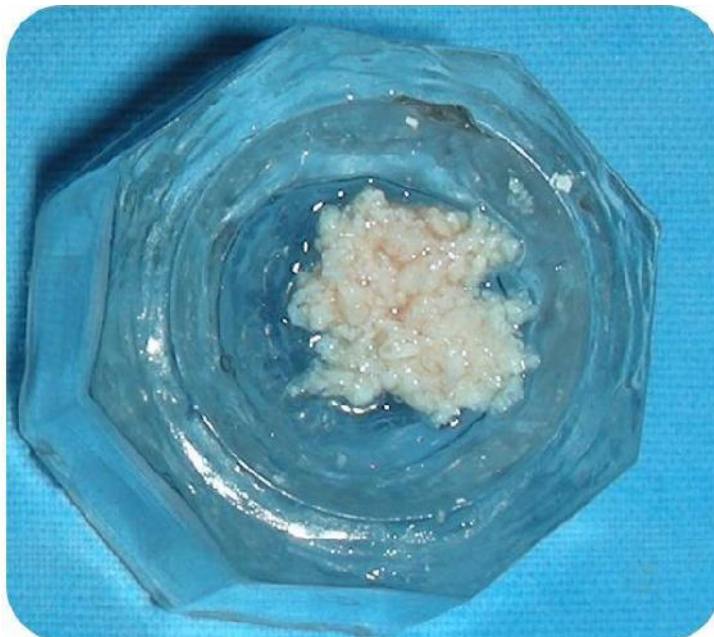
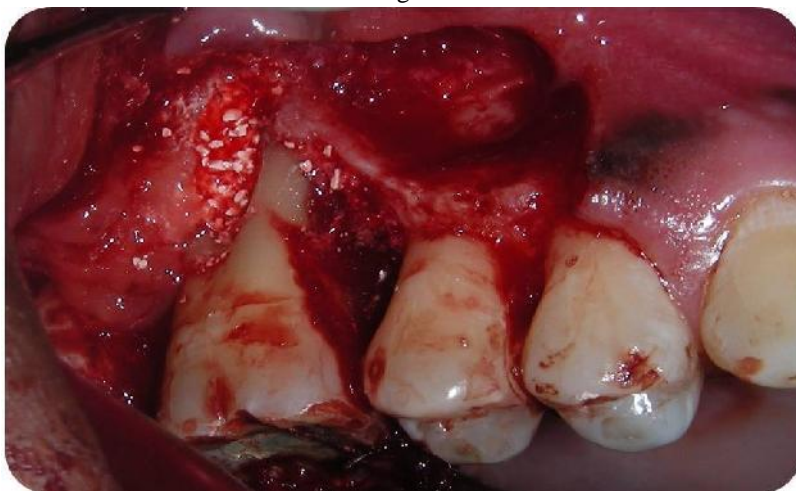
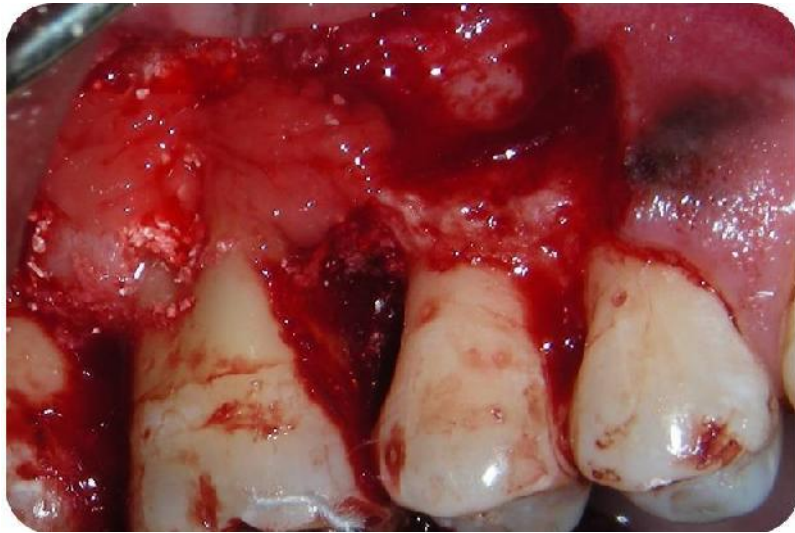Fig.9



closure, thereby retarding healing and possibly resulting in loss of the graft material. This was followed by placement of PPP over the defect [Fig.10.] The mucoperiosteal flap was replaced and primary wound closure was achieved by means of black silk 4-0 sutures and placement of Coe-Pak

TM (GC America, Alsip, IL, USA) to stabilise the surgical wound created and to ensure isolation and prevent bacterial contamination to fasten the process of healing . After a period of 7 to 10 days, the sutures were removed.



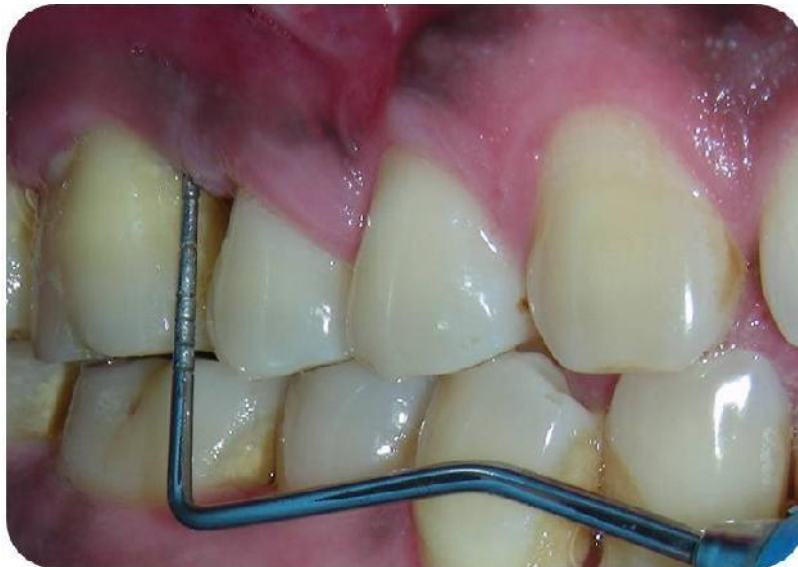Post operative care

Following surgery, the patient was instructed to avoid chewing in the surgical area during the first post operative day. Systemic antibiotics (Amoxicillin 500 mg, 3 times a day for 5 days) and analgesics (Ibuprofen 400 mg, 2 times a day for 3 days) were prescribed. The patient was instructed to rinse daily with a solution of 0.2% chlorhexidine digluconate for 7 days. Recall appointments were scheduled after 10 days and at 3, 6 and 12 months' interval.

Healing

The patient showed good compliance and satisfactory oral hygiene maintenance during follow-up period. The healing was uneventful, without any signs of infections and complications, indicating biocompatibility of both graft materials. After 10 days, the sutures were removed and healing was found to be adequate. Re-evaluation of the patient after 3, 6 and 12 months revealed complete soft tissue healing. The probing depth reduced from 8 mm to 3 mm [Fig.11]. The biological principle was based upon the use of mechanical barriers to allow selective cell repopulation of the root surface by periodontal ligament cells as proposed by Melcher.¹⁹

Fig.11



The mechanism of periodontal regeneration till date remains a complex and elusive phenomenon. To understand it further, the present case report evaluated the clinical and radiographic efficacy of autologous PRF and bovine derived bone matrix in the treatment of an intrabony defect. The only concern regarding bovine derived xenograft is for its nature of origin i.e. it is obtained from a donor of different species and may result in cross species antigenicity. However, the histological evaluation by Sogal A, Tofe AJ (1999)²⁰ confirmed a good tolerance and tissue acceptance of xenografts.

Platelet rich fibrin, the latest platelet concentrate developed by Choukroun et al (2001)² in France, concentrates 97 % of platelets and >50 % of leukocytes in a specific three dimensional distribution. It consists of intimate assembly of cytokines, glycanic chains and structural glycoproteins enmeshed within a slowly polymerized fibrin network.⁶

In an in- vitro comparison of PRF with PRP, He et al (2009)⁷ demonstrated gradual extended release of autologous growth factors such as PDGF and TGF- β and better induction of osteoblastic differentiation and proliferation by PRF. The inexpensive nature of PRF, less time consuming and less technique sensitive procedure for its preparation and favourable molecular properties makes PRF an obvious choice for regenerative therapy.

In the present report, a considerable reduction in PPD and CAL gain with minimal recession (1 mm) was observed 9 months post-operatively suggesting the arrest of disease activity and its progression. Thus, the results of present report support the role of various growth factors present in the PRF in accelerating the healing process.

The three walled component of the defect (towards apex), provided the best spatial relationship for bridging of the graft material with the vascular and cellular elements from the periodontal ligament and adjacent osseous wall.²¹

Also, space maintenance as provided by the defect walls helped to keep the PRF membrane in stable position thus providing protection and retention to the grafted material. Use of PRF as membrane to cover the apical two walled defect also appeared to be a successful adjunct to the maintenance of defect boundary as minimal recession and good bone fill was observed post-operatively.

Choukroun et al (2006)³ in his histological evaluation on effect of PRF on bone allograft in sinus lift procedure reported a reduced healing time to 4 months with the addition of PRF, thus, suggesting rapid healing and osteogenic ability of PRF. The observations of present case report are in accordance with Choukroun's above mentioned study and the recently reported comparative studies

Simple, easy, fast and cost effective process of PRF preparation without any biochemical involvements hold the major advantage over other derivatives. Also, the physiologically functional fibrin matrix has the ability to sustain and progressively release growth factors, cytokines and leukocytes in the surrounding tissues as the matrix degrades over time. All these factors help make Platelet Rich Fibrin the most significant in fibrin technology and endogenous regenerative therapy.²¹

Conclusion

Amongst the commercially available graft materials, Platelet Rich Fibrin appears to be the most advantageous. Its properties of being the completely natural, physiologic and economical source of autologous growth factors and cytokines makes it the most sought after treatment option currently available.

From the above report, it can be concluded that the combination of PRF and bone graft can be efficaciously used in the treatment of a periodontal intra-bony defects with significantly improved clinical parameters. The use of combination technique also promises additional benefit of rapid and early bone formation. However, clinical trials with larger sample size and confirmatory histological evaluations are required to better assess the clinical benefits of combination approach using PRF with bone grafts.

References

1. Giannobile WV. The potential role of growth and differentiation factors in periodontal regeneration. *J Periodontol* 1996;67:545-553.
2. Choukroun J, Adda F, Schoeffler C, et al. PRF: An opportunity in perio-implantology (in French). *Implantodontie* 2000;42:55-62.
3. Choukroun J, Diss A, Simonpieri A, et al. Platelet-rich fibrin (PRF): A second-generation platelet concentrate. Part IV: Clinical effects on tissue healing. *Oral Surg Oral Med Oral Pathol Oral Radiol Endod* 2006;101:56-60.
4. Choukroun J, Diss A, Simonpieri A, et al. Platelet-rich fibrin (PRF): A second-generation platelet concentrate. Part V: Histologic evaluations of PRF effects on bone allograft maturation in sinus lift. *Oral Surg Oral Med Oral Pathol Oral Radiol Endod* 2006;101:299-303.
5. Dohan Ehrenfest DM, Del Corso M, Diss A, et al. Three-dimensional architecture and cell composition of a Choukroun's platelet-rich fibrin clot and membrane. *J Periodontol* 2010;81:546-555.
6. Dohan Ehrenfest DM, de Peppo GM, Doglioli P, et al. Slow release of growth factors and thrombospondin-1

- in Choukroun's platelet rich plasma. *Journal of Periodontology* 2002;73:423-432.
- standard to achieve for all surgical platelet concentrates technologies. *Growth Factors* 2009;27:63-69.
7. He L, Lin Y, Hu X, et al. A comparative study of platelet-rich fibrin (PRF) and platelet-rich plasma (PRP) on the effect of proliferation and differentiation of rat osteoblasts in vitro. *Oral Surg Oral Med Oral Pathol Oral Radiol Endod* 2009;108:707-713.
 8. Diss A, Dohan DM, Mouhyi J, et al. Osteotome sinus floor elevation using Choukroun's platelet-rich fibrin as grafting material: A 1-year prospective pilot study with micro-threaded implants. *Oral Surg Oral Med Oral Pathol Oral Radiol Endod* 2008;105:572-579.
 9. Mazor Z, Horowitz RA, Del Corso M, et al. Sinus floor augmentation with simultaneous implant placement using Choukroun's PRF (Platelet-Rich Fibrin) as sole grafting material: A radiological and histological study at 6 months. *J Periodontol* 2009;80:2056-2064.
 10. Valentini P, Abensur D, Wenz B, et al. Sinus grafting with porous bone mineral (Bio-Oss): a study on 15 patients. *International Journal of Periodontics & Restorative Dentistry* 2000;20:245-252.
 11. Piattelli M, Favero GA, Scarano A, et al. Bone reactions to anorganic bovine bone (Bio-Oss) used in sinus augmentation procedures: A histologic long-term report of 20 cases in humans. *International Journal of Oral and Maxillofacial Implants* 1999;14:835-840.
 12. Zitzmann NU, Scharer P, Marinello CP, et al. Alveolar ridge augmentation with Bio-Oss histological study in humans. *International Journal of Periodontics & Restorative Dentistry* 2001;21:289-295.
 13. Hammerle CHF, Chiantella GC, Karring T, et al. The effect of a deproteinized bovine bone mineral on bone regeneration around titanium dental implants. *Clinical Oral Implants Research* 1998;9:151-162.
 14. S Camelo M, Nevins ML, Schenk RK, et al. Clinical, radiographic, and histologic evaluation of human periodontal defects treated with Bio-Oss and Bio-Gide. *International Journal of Periodontics & Restorative Dentistry* 1998;18:321-331.
 15. Mellonig JT. Human histologic evaluation of a bovine-derived bone xenograft in the treatment of periodontal osseous defects. *International Journal of Periodontics & Restorative Dentistry* 2000;20:19-29.
 16. Hutchens LH Jr. The use of a bovine bone mineral in periodontal osseous defects: Case reports. *Compendium of Continuum Education in Dentistry* 1999;20:365-378.
 17. Richardson CR, Mellonig JT, Brunsvold MA, et al. Clinical evaluation of Bio-Oss: A bovine-derived xenograft for the treatment of periodontal osseous defects in humans. *Journal of Clinical Periodontology* 1999;26:421-428.
 18. Scheyer ET, Velasquez-Plata D, Brunsvold MA, et al. A clinical comparison of a bovine-derived xenograft used alone and in combination with enamel matrix derivative for the treatment of periodontal osseous
 19. Melcher AH. On the repair potential of periodontal tissues. *J Periodontol* 1976;47:256-260.
 20. Sogal A, Tofe AJ. Risk assessment of bovine spongiform encephalopathy transmission through bone graft material derived from bovine bone used for dental applications. *J Periodontal* 1999;70(9):1053-1063.
 21. Blumenthal N, Sabet T, Barrington E. Healing responses to grafting of combined collagen. *J Periodontol* 1986;57:84-94.
 22. AR Pradeep, Bajaj P, Rao NS, et al. Platelet rich fibrin combined with a porous hydroxyapatite graft for the treatment of 3-walled Intra-bony defects in chronic periodontitis: A Randomized Controlled clinical trial. *J Periodontal* 2012 (ahead Of print).
 23. Lekovic V, Camargo Pm, Weinlaender M, et al. Comparison of platelet rich plasma and bovine porous bone mineral in the treatment of intra-bony defects: A re-entry study. *J Periodontal* 2002;73:198-205.