

Research Article

DOI: <http://dx.doi.org/10.22192/ijamr.2019.06.03.004>

## Importance of diagnosis and planning in oral rehabilitation of the anterior sector.

Germán Ralph Padilla Cruz<sup>1\*</sup>, Elva Soledad Mancilla Mejía<sup>2</sup>  
y Paola Rosalinda Álvarez Guerrero.<sup>3</sup>

<sup>1\*</sup>, <sup>2</sup> Residents of second year oral prosthesis in the Post graduate School of Naval Health, Naval University and the Naval Medical Center, Secretariat of Armed Marine of Mexico (SEMAR).

<sup>3</sup> Specialist in restorative dentistry of the Naval Medical Center, Secretary of the Navy of México (SEMAR), Mexico.

\*Correspondence: Cd. Germán Ralph Padilla Cruz. E-mail: [ralphpc2202@gmail.com](mailto:ralphpc2202@gmail.com)

### Abstract

#### Keywords

Diagnosis;  
Oral Rehabilitation;  
Stomatognathic  
System;  
Mock-Up.

**Introduction:** The diagnosis, adequate and the execution of dental restoration in the anterior segment, is a subject of vital importance in the development of reliable treatment plans and with predictable results in fundamental aspects such as biological, functional and aesthetic integration. The implementation techniques are based on the objective of the treatment.

**Objective:** to make known the importance of performing an adequate diagnosis and treatment plan that allows analyzing the aesthetic parameters of the patient, assessing the existing problems in the oral cavity and exercising a new alternative for the development of more predictable treatments.

**Presentation of the clinical case:** A 45-year-old male patient presented aesthetic restorations on teeth 11 and 21 with 4 years old in poor condition.

### Background

The diagnosis is the determination of the nature of a disease, in prosthesis is the reproduction of some part of the oral or facial cavity for the purpose of study and planning of treatment defining it as the sequence of planned procedures.<sup>1</sup>

The Prosthodontics is the branch of Dentistry whose objective is the diagnosis, planning of treatment, rehabilitation and maintenance of the function, aesthetics and health of patients with clinical conditions associated with the lack of teeth or deficient and / or maxillofacial tissues using biocompatible substitutes.<sup>1</sup>

The prosthetic rehabilitation should be done by studying four parameters: aesthetics, function, tooth structure and biology or oral health.<sup>2,3</sup>

According to Spear, the diagnostic sequence should begin with the aesthetic study and continue with the functional, structural and biological study. However, the sequence of the treatment plan would be opposite, that is, start treating the biological problems to restore oral health (elimination of caries, modification of the bone and / or gums, endodontics or extractions), continue with the restoration of the defects structural

and the relocation of dental pieces, which will lead us to rehabilitate the function and aesthetics.<sup>4</sup>

A multidisciplinary approach is essential to obtain all the necessary perspectives and thus carry out a correct execution of the treatment. As dentists we must have knowledge of the aesthetic and functional principles of natural teeth in order to detect factors that may alter the structure of the smile, system function and phonetics.<sup>5</sup>

Several techniques have been designed to help clinicians and dental technicians determine the correct treatment plan for definitive restorations. This includes observation of soft tissues, gingival replicas and temporary restorations.<sup>6,7,8</sup>

The transfer of the aesthetic and functional parameters that are analyzed in a clinical trial allows the direct evaluation by both the patient and the professional of the desired result; this procedure improves patient-clinical-laboratory communication, avoids speculation.<sup>9</sup>

### Presentation of the clinical case

- 45 year old male patient.
- Personal pathological background: questioned and denied.
- Personal non-pathological background: interrogated and denied.
- Goes to the specialty of oral prosthesis in Naval Medical Center, for presenting esthetic restorations on teeth 11 and 21 with 4 years old, referring to wanting to change them since aesthetically they do not like, but has a limited budget.
- Clinically gingival tissues of the upper anterior hyperplastic sector are observed due to over contouring and poorly sealed aesthetic restorations, medium gingival biotype, without pathological clinical data in hard tissue, Angle I Class, without left canine protection, right anterior cross bite, with protection mutual and group function, anterior contact in centric occlusion of 2 mm to vertical and horizontal overlap, absence of tooth 23, presence of multiple misaligned dental restorations and carious processes.

### Diagnosis and treatment:

- **Periodontal Dx:** gingival tissues of the anterior superior sector according to Coslet with passive eruption type 1 subgroup B plus gingival enlargement in upper anterior sector induced by dentobacterial plaque.
- **Prosthetic Dx:** middle line deviated, medium smile, free metal crowns of teeth 11 and 21 mismatched and resins with filtration on teeth 12 and 22.
- **Tx Qx:** crown lengthening of the upper anterior sextant.
- **Prosthetic Tx:** temporization with mock-up (protemp 5), placement of e-maxlithium disilicate crowns stratified on teeth 12, 11, 21 and 22, resin veneers on teeth 13 and 24.

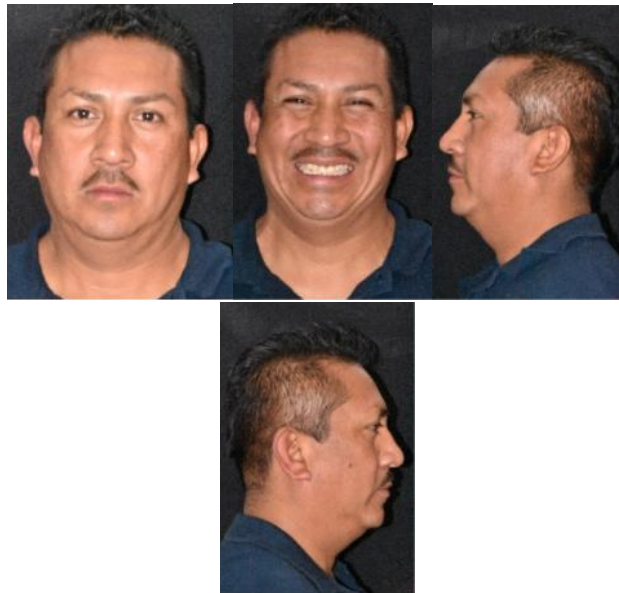### Conclusion

Due to the complexity of the upper anterior sector (esthetic zone) it is essential to consider the aesthetics and functionality of the dental pieces, therefore, it is essential to make an adequate diagnosis and treatment plan in order to return the patient to proper functioning of the stomatognathic system without overlooking aesthetics.

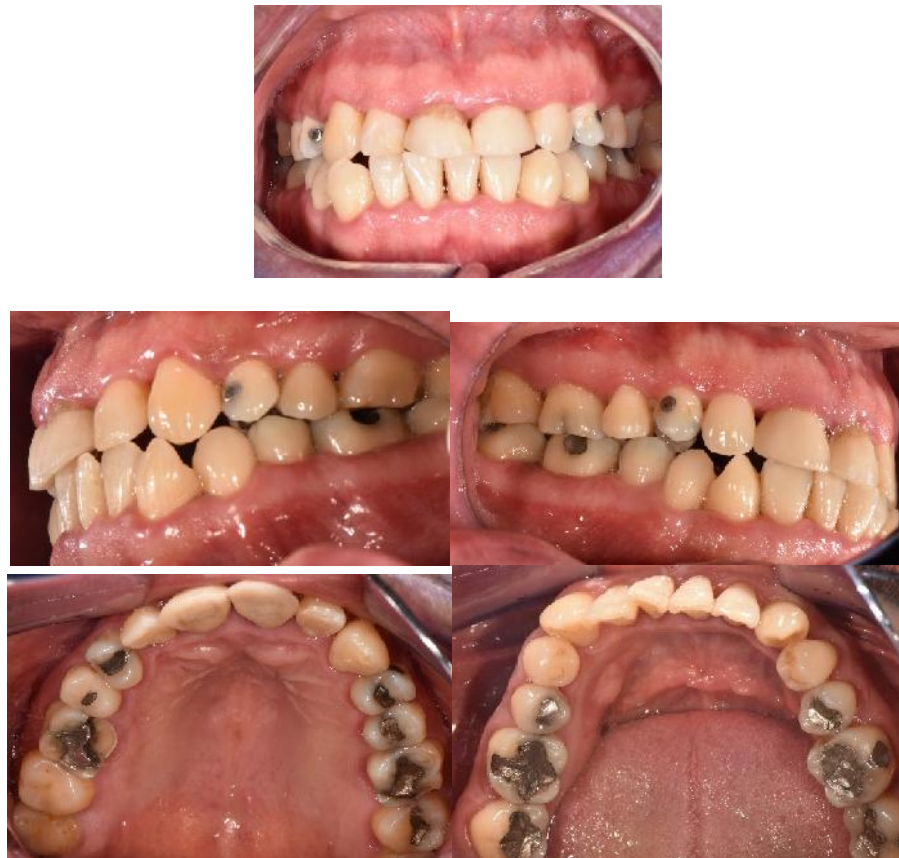In the clinical case presented, the patient stated that he had poor prostheses because they did not allow him to perform a good sanitation, causing discomfort and difficulty at the time of feeding and aesthetically they were not to his liking. It was decided to perform a Mock Up (sketch) which allows us to predict, evaluate and define the treatment in order to meet the needs of the patient by restoring the entire stomatognathic system with the ideal aesthetic, thus achieving success in rehabilitation. The general objective of this work is to make known the importance of making an adequate diagnosis and treatment plan that allows to analyze the aesthetic parameters of the patient, evaluate the existing problems in the oral cavity and exercise a new alternative for the development of more predictable treatments .

**Annexes:**

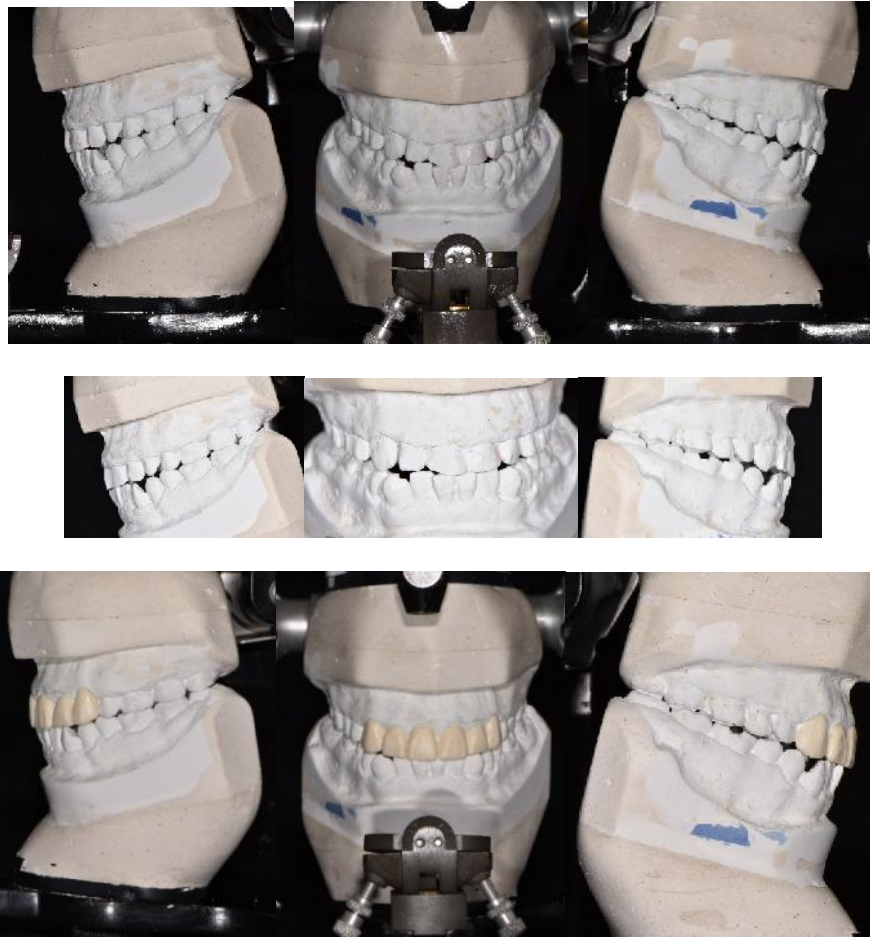
**Extraoral photos:**



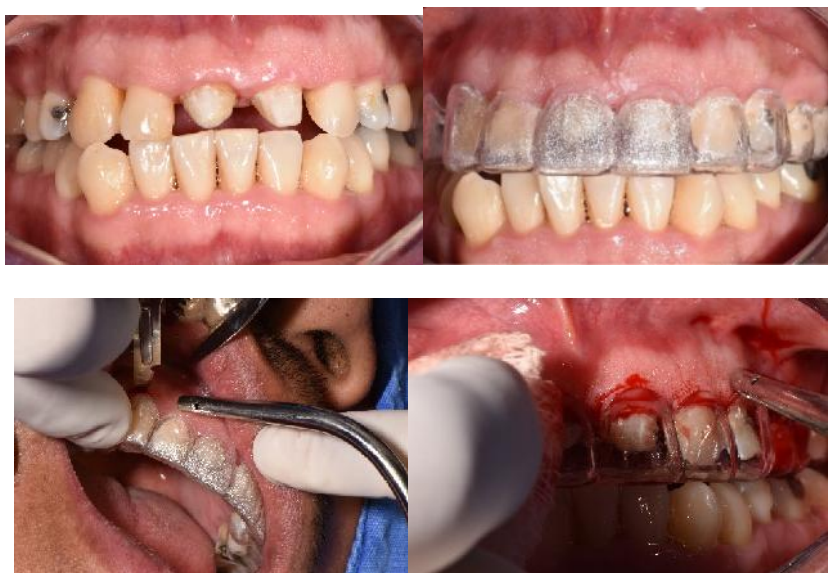**Intraoral photos before treatment:**

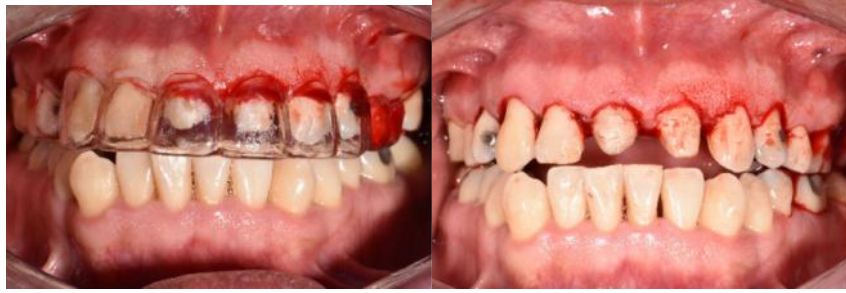

**Assembly and waxing:**

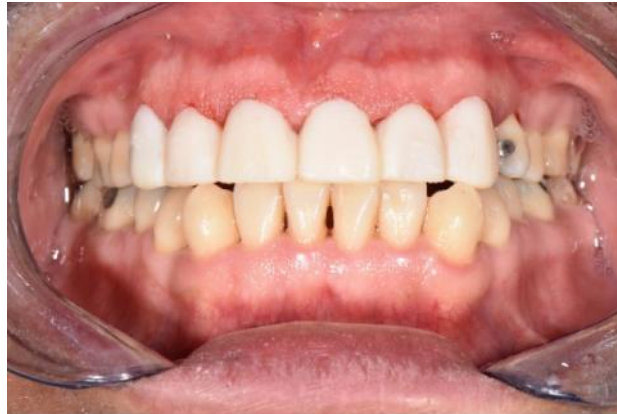

**Surgical procedure:**

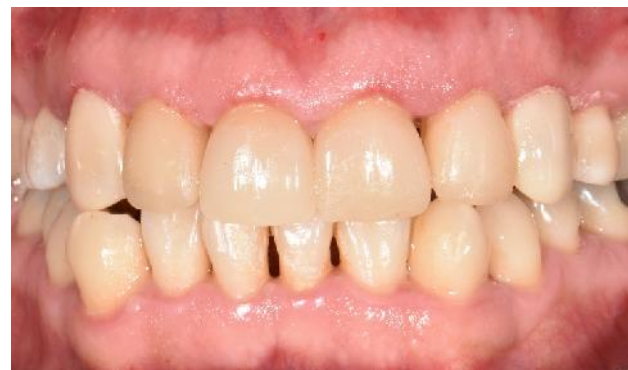
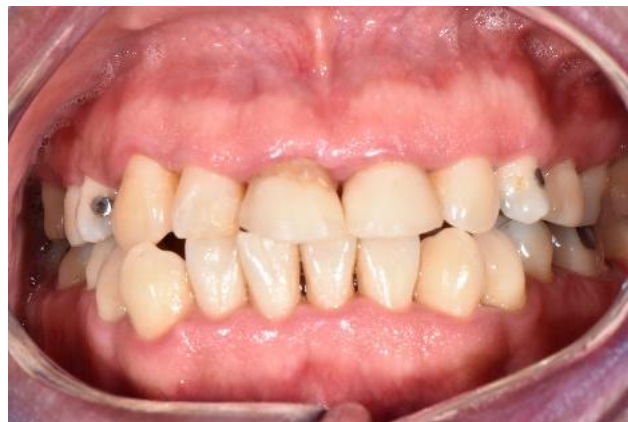


**Provisionalization (mock-up):**




**Treatment results:**



**Bibliographic References**

1. The Academy of Prosthodontic. The Glossary of Prosthodontic Terms. J of Prosthetic Dent. 2017; 117 (1): 10-105.
2. Carlos Mas Bermejo, Carlos Mas Gómez, Rehabilitación Protésica Bucal desde el Punto de Vista Funcional. Revisión bibliográfica, Dossier 2014: 1-11
3. Garcia, sexto, Orrego, Gissel, Parámetros Estéticos del Perfil Facial: El Angulo Nasolabial, Kiru. 2014, 11 (1):86-9
4. Spear FM, Kokich VG, Mathews DP. Interdisciplinary Management of Anterior Dental Esthetics .Adv Esthetics and Inter Dent 2006. 2(4): 6-20.
5. Fradeani, Mauro, Rehabilitación Estética en Prosdodncia Fija, 2009, Quintessence, 1ra Ediccion Barcelona
6. Orellana MB, Cuellar FV, Soria LMC. Mock Up – como Herramienta de Planeamiento en Rehabilitación Oral. J OrofacInvest. 2017;4(2): 21-40.
7. Bidra AS. A technique for transferring a patient's smile line to a conebeam computedtomography (CBCT) image. J Prosthet Dent. 2014 Aug;112(2):108-11.
8. Coachman, C, Calamita, M, diseño de sonrisa digital, una herramienta para la planificación y el tratamiento 2012.
9. Bidra AS. A technique for transferring a patient's smile line to a conebeam computedtomography (CBCT) image. J Prosthet Dent. 2014 Aug;112(2):108-11.

Access this Article in Online	
	Website: <a href="http://www.ijarm.com">www.ijarm.com</a>
	Subject: Dentistry
Quick Response Code	
DOI: <a href="https://doi.org/10.22192/ijamr.2019.06.03.004">10.22192/ijamr.2019.06.03.004</a>	

How to cite this article:

Germán Ralph Padilla Cruz, Elva Soledad Mancilla Mejía, y Paola Rosalinda Álvarez Guerrero. (2019). Importance of diagnosis and planning in oral rehabilitation of the anterior sector. Int. J. Adv. Multidiscip. Res. 6(3): 21-26.

DOI: <http://dx.doi.org/10.22192/ijamr.2019.06.03.004>